

## Distinct neuroanatomical bases of episodic and semantic memory performance in Alzheimer's disease

Daniela I. Hirni<sup>a,b</sup>, Sasa L. Kivisaari<sup>a,b</sup>, Andreas U. Monsch<sup>a,b</sup>, Kirsten I. Taylor<sup>a,b,c,\*</sup>

<sup>a</sup> Memory Clinic, Department of Geriatrics, University Hospital Basel, Schanzenstrasse 55, 4031 Basel, Switzerland

<sup>b</sup> University of Basel, Petersplatz 1, 4003 Basel, Switzerland

<sup>c</sup> Centre for Speech, Language and the Brain, Department of Experimental Psychology, Downing Street, Cambridge CB2 3EB, UK

### ARTICLE INFO

#### Article history:

Received 22 October 2012

Received in revised form

17 January 2013

Accepted 20 January 2013

Available online 29 January 2013

#### Keywords:

Alzheimer's disease

Episodic memory

Semantic memory

Perirhinal cortex

Entorhinal cortex

Hippocampus

### ABSTRACT

Alzheimer's disease (AD) neurofibrillary pathology begins in the medial perirhinal cortex (mPRC) before spreading to the entorhinal cortex (ERC) and hippocampus (HP) in anterior medial temporal lobe (aMTL). While the role of the ERC/HP complex in episodic memory formation is well-established, recent research suggests that the PRC is required to form semantic memories of individual objects. We aimed to test whether commonly used clinical measures of episodic and semantic memory are distinctly associated with ERC/HP and mPRC integrity, respectively, in healthy mature individuals and very early AD patients. One hundred thirty normal controls, 32 amnesic mild cognitive impairment patients, some of whom are in the earliest (i.e., preclinical) stages of AD, and ten early-stage AD patients received neuropsychological testing and high-resolution anatomic and diffusion MRI. Voxel-based regression analyses tested for regions where episodic memory (delayed recall scores on the California Verbal Learning and Rey Osterrieth Complex Figure Tests) and semantic memory (Boston Naming Test, category fluency) performance correlated with gray matter (GM) regions of interest and whole-brain fractional anisotropy (FA) voxel values. When controlling for the opposing memory performance, poorer episodic memory performance was associated with reduced bilateral ERC/HP GM volume and related white matter integrity, but not with mPRC GM volume. Poor semantic memory performance was associated with both reduced left mPRC and ERC/HP GM volume, as well as reduced FA values in white matter tracts leading to the PRC. These results indicate a partial division of labor within the aMTL and suggest that mPRC damage in very early AD may be detectable with common clinical tests of semantic memory if episodic memory performance is controlled.

© 2013 Elsevier Ltd. All rights reserved.

### 1. Introduction

A major goal in Alzheimer's disease (AD) research is to identify the earliest cognitive changes in the disease which would allow current and future therapies to be initiated when they are expected to be maximally beneficial. Currently, impairments in episodic memory performance are considered the first clinical sign of AD, and are associated with atrophy of the entorhinal cortex (ERC) and hippocampus (HP) (i.e., ERC/HP complex; Killiany et al., 2002; Petersen et al., 2000). Importantly, AD neurofibrillary pathology affects the more medial portion of the perirhinal cortex (PRC) before it spreads to the ERC and HP (Braak

& Braak, 1995; Taylor & Probst, 2008). Recent research suggests that the PRC may be involved in a different kind of memory processing, namely, semantic memories for individual objects (Murray & Richmond, 2001; Taylor, Moss, Stamatakis, & Tyler, 2006; Tyler et al., 2004). However, it is unclear whether this functional-anatomical dissociation can be observed with commonly used clinical tests in the context of early AD. Therefore, the aim of this cross-sectional study was to determine whether episodic memory and semantic object memory functioning as measured by common clinical neuropsychological tests are distinctly associated with the ERC/HP and medial PRC (mPRC) integrity, respectively, in healthy control participants (NC) and patients with suspected early AD.

Isolated episodic memory dysfunction as manifested in the amnesic Mild Cognitive Impairment (aMCI) syndrome represents a preclinical stage of AD (Petersen, 2004; Winblad et al., 2004). Indeed, the cognitive measures which decline earliest during the course of AD are typically delayed recall scores from tests of verbal and nonverbal episodic memory (Salmon, 2011; Saxton

\* Correspondence at: Memory Clinic, Department of Geriatrics, University Hospital Basel, Schanzenstrasse 55, CH-4031 Basel, Switzerland.  
Tel.: +41 61 265 89 42; fax: +41 61 265 37 88.

E-mail addresses: [HirniD@uhbs.ch](mailto:HirniD@uhbs.ch) (D.I. Hirni), [KivisaariS@uhbs.ch](mailto:KivisaariS@uhbs.ch) (S.L. Kivisaari), [andreas.monsch@unibas.ch](mailto:andreas.monsch@unibas.ch) (A.U. Monsch), [kirsten.taylor@usb.ch](mailto:kirsten.taylor@usb.ch) (K.I. Taylor).

et al., 2004), such as the California Verbal Learning Tests (CVLT) (Delis, Kramer, & Ober, 1987), the Buschke Selective Reminding Test (Buschke & Fuld, 1974) and the Rey Osterrieth Complex Figure (ROCF) test (Osterrieth, 1944). Recent models of anterior medial temporal lobe (amTL) function posit that episodic memory formation is critically underpinned by the HP and ERC (Eichenbaum, Dudchenko, Wood, Shapiro, & Tanila, 1999; Lipton & Eichenbaum, 2008). Consistent with such models, poor episodic memory performance in early-stage AD patients is associated with decreased volume of the ERC and/or HP (Davies, Graham, Xuereb, Williams, & Hodges, 2004; Killiany et al., 2002; Petersen et al., 2000).

AD neurofibrillary pathology starts neither in the ERC nor in the HP, but in the transentorhinal cortex representing the medial aspect of the PRC (Braak & Braak, 1991; Gertz et al., 1998; Taylor & Probst, 2008), suggesting that cognitive functions associated with the PRC may be additionally important for the early detection of AD. The PRC receives dense inputs from the visual object processing stream and also information from unimodal and polymodal sensory areas (Suzuki & Amaral, 1994). Research in primarily non-human primates suggests that the PRC binds this information together to form complex, multimodal object representations (Lavenex & Amaral, 2000; Murray, Malkova, & Goulet, 1998; Parker & Gaffan, 1998) which may correspond to human semantic object memories (Murray et al., 1998; Murray & Richmond, 2001). Recent human cognitive neuroscientific studies support this account. For example, Taylor et al. (2006) observed greater PRC activity when healthy participants performed a crossmodal integration task with features belonging to living things (e.g., a picture of a cat and the sound “meow”) compared to features belonging to nonliving things (e.g., a picture of a telephone and a ringing sound), and greater activity for meaningfully unrelated than meaningfully related stimuli. Thus, PRC responses were sensitive to the meaning (semantics) of the multimodal objects. Furthermore, a voxel-based correlational analysis with brain-damaged patients showed that decreased integrity of amTL regions, including the PRC, was similarly associated with poorer integration of crossmodal features of living compared to nonliving and meaningfully unrelated compared to meaningfully related stimuli (Taylor, Stamatakis, & Tyler, 2009). Finally, atrophy of the amTL including the PRC in semantic dementia patients correlated with performance on common clinical tests of semantic object memory, including confrontation naming and animal category fluency (Davies et al., 2004). Taken together, these findings suggest that the human PRC binds different object features together to form meaningful multimodal object representations which may correspond to semantic memories of individual objects (Kivisaari, Probst, & Taylor, in press; Taylor et al., 2006; Taylor, Devereux, & Tyler, 2011; see also Wang, Lazzara, Ranganath, Knight, & Yonelinas, 2010).

An outstanding question and aim of the present study was to determine whether commonly used clinical measures of episodic and semantic memory functioning are differentially related to the integrity of the ERC/HP and mPRC, respectively in healthy participants and very early AD patients. We studied patients with early-stage AD as well as patients with aMCI, many of whom progress to AD (Petersen, 2004; Winblad et al., 2004), since both patient groups are presumed to have amTL pathology. We correlated clinical measures of episodic (i.e., CVLT and ROCF delayed recall) and semantic (i.e., Boston Naming Test (BNT) and category verbal fluency of animals (CVFA) memory performance with measures of gray and white matter (GM and WM, respectively) integrity in NC, aMCI and AD patients. We directly tested whether the mPRC and ERC/HP complex are differentially associated with clinical tests of semantic and episodic memory using GM region of interest (ROI) analyses. In addition we used

whole-brain voxel-based FA analyses to determine whether WM tracts associated with the mPRC and ERC/HP complex were likewise associated with semantic and episodic memory performance, respectively. Because these processes are partially interdependent (i.e., episodic memory aids retrieval from semantic memory, and semantic memories enrich episodic memories) and thus engage similar brain regions (Greenberg, Keane, Ryan, & Verfaellie, 2009; Greenberg & Verfaellie, 2010; Ryan, Cox, Hayes, & Nadel, 2008), we also aimed to determine the unique neural correlates of episodic and semantic memory performance by controlling for the contrasting memory performance. We hypothesized that episodic memory performance is related to ERC/HP integrity and semantic memory performance to mPRC integrity. Since neurofibrillary pathology in AD starts in the mPRC before extending into the ERC and HP (Braak & Braak, 1991), confirmation of these hypotheses would indicate that widely used clinical measures of semantic object memory may be useful for the very early detection of AD.

## 2. Method

### 2.1. Participants

Data from 130 NCs were included in this study. All participants were members of longitudinal research studies on aging and dementia at the Memory Clinic, Department of Geriatrics at the University Hospital Basel (Monsch et al., 2000). All NC participants were cognitively and neurologically healthy, i.e., none suffered from severe sensory or motor deficits, severe systemic diseases, continuous mild to intense pain, current psychiatric problems, current or past diseases of the central nervous system, or diseases or states which potentially negatively impacted on central nervous system activity including depression according to the Diagnostic and Statistical Manual of Mental Disorders (DSM) IV criteria (American Psychiatric Association, 1994).

Data from 42 members of the same research studies with diagnoses of aMCI ( $n=32$ ) and probable AD ( $n=10$ ) were also included in the analyses. aMCI patients were diagnosed according to Winblad et al. (2004) criteria and probable AD patients according to the criteria outlined by the National Institute for Neurological and Communicative Disorders and Stroke and the Alzheimer's Disease and Related Disorders Association (McKhann et al., 1984) and DSM-IV (American Psychiatric Association, 1994). Medical and psychiatric examinations ruled out concomitant neurologic or psychiatric diseases.

All participants were native German speakers. The three groups did not differ with respect to the demographic characteristics of age, education and gender, but significantly differed, as expected, with respect to their MMSE (Mini-Mental Status Examination) scores (Folstein, Folstein, & McHugh, 1975) (see Table 1). This study was approved by the local Ethics Committee of Both Basel (EKBB) and written informed consent was obtained from all participants.

### 2.2. Neuropsychological tests

All participants were administered all subtests of the German version of the Consortium to Establish a Registry for Alzheimer's Disease-Neuropsychological Assessment Battery (CERAD-NAB, Morris et al., 1989) with the exception of the figures and word-list subtests. This battery included the short version of BNT (Morris et al., 1989) and 1 min CVFA (“animal fluency”; Lezak, Howieson, Loring, Hannay, & Fischer, 2004; Morris et al., 1989). All participants were additionally administered the German version of the CVLT (Delis et al., 1987) and the ROCF test (Osterrieth, 1944). Four neuropsychological measures reflecting recall from episodic and semantic memory, described below, were selected for the present analyses.

#### 2.2.1. Episodic memory

**2.2.1.1. German version of the California Verbal Learning Test (CVLT).** The CVLT (Delis et al., 1987) presents a shopping list containing 16 items (List A), which are read aloud to the participant five times. After each trial, participants are instructed to recall as many words as possible. After the last trial, a second word list (List B) is verbally presented, followed by an immediate free recall of List B, then a free recall and afterwards cued (category labels) recall of List A items. After a delay of circa 20 min, participants are instructed to freely recall List A words, followed by a cued recall with category labels (Delis et al., 1987). For the present study, scores on the

**Table 1**  
Demographic characteristics, MMSE scores, and episodic and semantic memory performance measures (means  $\pm$  standard deviations; maximal scores noted in square brackets; each group's age, gender and education-corrected z-score noted parenthetically) in the NC, aMCI and AD groups.

	Diagnosis			Significance $F/\chi^2$ (p-value)
	NC N=130	aMCI N=32	AD N=10	
<b>Demographic characteristics</b>				
Age (y)	71.9 $\pm$ 8.0	72.5 $\pm$ 8.6	67.3 $\pm$ 11.2	3.0 (0.2) <sup>f</sup>
Education (y)	13.4 $\pm$ 2.7	13.8 $\pm$ 3.4	13.5 $\pm$ 3.5	0.3 (0.7)
Gender (female:male)	46:84	14:18	6:4	2.9 (0.2) <sup>f</sup>
MMSE <sup>a</sup> [30]	29.2 $\pm$ 1.1	28.8 $\pm$ 1.0	26.5 $\pm$ 1.8	24.8 <sup>f</sup> (< 0.001)
<b>Episodic memory measures</b>				
CVLT <sup>b</sup> (raw score) [16]	12.7 $\pm$ 2.7	7.5 $\pm$ 2.9	3.8 $\pm$ 3.5	67.9 <sup>f</sup> (< 0.001)
CVLT <sup>b</sup> (z-score)	(0.4 $\pm$ 1.0)	(-1.6 $\pm$ 0.9)	(-3.2 $\pm$ 1.1)	
ROCF <sup>c</sup> (raw score) [36]	20.6 $\pm$ 6.0	14.2 $\pm$ 6.5	5.9 $\pm$ 6.0	10.2 <sup>f</sup> (< 0.001)
ROCF <sup>c</sup> (z-score)	(0.4 $\pm$ 1.0)	(-0.7 $\pm$ 0.9)	(-2.3 $\pm$ 1.2)	
Mean episodic memory (z-score)	0.3 $\pm$ 0.6	-0.8 $\pm$ 0.7	-1.8 $\pm$ 0.6	70.4 <sup>f</sup> (< 0.001)
<b>Semantic memory measures</b>				
CVFA <sup>d</sup> (raw score)	24.0 $\pm$ 5.5	20.2 $\pm$ 5.9	14.4 $\pm$ 2.5	18.2 (< 0.001)
CVFA <sup>d</sup> (z-score)	(0.5 $\pm$ 1.0)	(-0.2 $\pm$ 1.1)	(-1.6 $\pm$ 0.8)	
BNT correct <sup>e</sup> (raw score) [15]	14.5 $\pm$ 0.7	13.3 $\pm$ 1.4	13.3 $\pm$ 1.2	29.0 <sup>f</sup> (< 0.001)
BNT correct <sup>e</sup> (z-score)	(0.4 $\pm$ 0.8)	(-0.5 $\pm$ 1.0)	(-0.8 $\pm$ 0.9)	
Mean semantic memory (z-score)	0.2 $\pm$ 0.7	-0.6 $\pm$ 1.0	-1.1 $\pm$ 0.6	35.9 <sup>f</sup> (< 0.001)

<sup>a</sup> MMSE=Mini-Mental State Examination (Folstein et al., 1975).

<sup>b</sup> CVLT=German version of the California Verbal Learning Test, Long Delay Free Recall (Delis et al., 1987).

<sup>c</sup> ROCF=Rey-Osterrieth Complex Figure, Long Delay Free Recall (Osterrieth, 1944).

<sup>d</sup> CVFA=Category Verbal Fluency Animals (Morris et al., 1989) in 1 min.

<sup>e</sup> BNT=short, 15-item version of the Boston Naming Test (Morris et al., 1989).

<sup>f</sup>  $\chi^2$ -test.

long-delay free recall subtest were selected as measures of episodic memory performance (Salmon & Bondi, 2008; Vargha-Khadem et al., 1997).

**2.2.1.2. Rey-Osterrieth Complex Figure (ROCF) test.** The ROCF test (Osterrieth, 1944) begins by asking participants to copy a complex figure on a sheet of paper. Participants are asked to redraw the figure from memory immediately after copying the figure and again after a 30–45 min delay. Reproductions are scored according to both spatial and figural criteria of the 18 details in the figure: two points are awarded for each correctly reproduced and correctly placed feature. Thus, the maximum score for each figure is 36 (Lezak et al., 2004). Long-delay free recall scores from this test were likewise used in the present analyses.

## 2.2.2. Semantic memory

**2.2.2.1. Short version of the Boston Naming Test (BNT).** The short version of the BNT in the CERAD-NAB (Morris et al., 1989) presents participants with 15 black-and-white line drawings for confrontation naming (Kaplan, Goodglass, Weintraub, & Segal, 1983). Failure to spontaneously name the picture leads to the administration of a semantic cue, and, if necessary, a phonemic cue. The total number of spontaneously correctly named line drawings was used as a measure of semantic memory functioning in the present analyses (Hodges, Salmon, & Butters, 1992).

**2.2.2.2. Category verbal fluency animals (CVFA).** The CVFA (Morris et al., 1989) requires participants to name as many animals as they can think of within 1 min. The number of correctly produced animal names within 1 min was used in the present analyses.

## 2.3. MRI measures

### 2.3.1. Scan acquisition

All participants underwent high-resolution T1-weighted three-dimensional magnetization-prepared rapid acquisition gradient echo (MPRAGE) anatomical imaging (TI=1000 ms, TR=2150 ms, TE=3.5 ms, flip angle=7°, rectangular field of view=87.5% (280  $\times$  245 mm<sup>2</sup>), acquisition matrix=256  $\times$  224 mm, voxel size: 1 mm isotropic). In addition, all but one of the NC participants and two of the aMCI patients underwent diffusion tensor imaging (DTI; single-shot echo-planar imaging (EPI), TR=4000 ms, TE=100 ms, matrix size=256  $\times$  128, 1st b-value=0, 2nd b-value=1030 s/mm<sup>2</sup>, two sets of 30 direction scans and six b-values=0, voxel size: 2.5 mm isotropic). Both sequences were acquired on a 3.0T MRI head scanner (MAGNETOM Allegra, Siemens) at the University Hospital Basel. MRI scanning

was conducted within three months of behavioral testing (mean=29.6 days, SD=19.1 days).

## 2.4. Analyses

### 2.4.1. Statistical analyses of behavioral data

Shapiro–Wilk tests determined that the raw CVFA scores were normally distributed ( $p > .05$ ), whereas the raw CVLT, ROCF and BNT scores were negatively skewed ( $D(172)=0.9$ ,  $p < .001$ ;  $D(172)=1.0$ ,  $p < .01$  and  $D(172)=0.8$ ,  $p < .001$ , respectively). Therefore, group differences on normally distributed behavioral scores were tested with a one-way analysis of variance (ANOVA) followed by a Hochberg's G T2 *post-hoc* test which accounts for differences in sample sizes, while group differences of non-normally distributed scores were tested nonparametrically with the Kruskal–Wallis test followed by Mann–Whitney *U post-hoc* tests. All statistical analyses of behavioral data were performed with IBM SPSS Statistics 19 software (SPSS Inc. and IBM company 2010).

### 2.4.2. Imaging analyses of gray matter

**2.4.2.1. Preprocessing of structural MR images.** Preprocessing of the structural brain images was performed using the DARTEL approach (Ashburner, 2007) in SPM8 (Wellcome Institute of Cognitive Neurology, www.fil.ion.ucl.ac.uk) implemented in Matlab 2010 (Mathworks Inc., Sherborn, MA, USA). The images were segmented into GM with bias correction. Masks were manually drawn on the tissue misclassified as GM around the aMTL and these areas were removed from the native space T1 images. These corrected native space T1 images were then again segmented into GM, WM and cerebrospinal fluid while masking deleted areas. The bias-corrected, re-segmented GM images were used to create a DARTEL GM template. Finally, the individual GM volumes were normalized to the common DARTEL template and MNI space including image modulation.

**2.4.2.2. ROI analyses.** To determine whether (a) episodic memory performance was significantly related to the integrity of the ERC/HP head and (b) semantic memory dysfunction to the integrity of the mPRC in the context of very early AD, *a priori* defined ROIs were created for the left and right ERC/HP head and mPRC. These ROIs were manually drawn on the DARTEL group template in MNI space based on anatomic landmarks described in Kivisaari et al. (in press). Mean signal intensities were calculated for each ROI and each participant using the fslstats script in fsl (FSL v4.1.6; <http://www.fmrib.ox.ac.uk/fsl>). To determine the general relationships between episodic and semantic memory performance and the integrity of the four ROI regions, we performed linear regression analyses using (a) episodic memory performance and (b) semantic memory performance to predict the mean signal intensity of each ROI. Both sets of analyses included age and total

intracranial volume (TIV) as covariates to control for age-related effects and effects due to head size, respectively.

Since cognitive processes involved in clinical tests of episodic and semantic memory overlap (Greenberg et al., 2009; Greenberg & Verfaellie, 2010), we performed a second set of linear regression analyses which tested for the unique predictive relationship between episodic memory performance and mean signal intensity in each ROI while controlling for the effect of semantic memory performance, and vice versa. These tests included the semantic and episodic memory measures described above, and age and TIV as covariates, in a single linear regression analysis for each ROI. The covariate results are not reported because they are not of primary theoretical interest.

To ensure an equal weighting of each neuropsychological measure, these were transformed into z-scores using the present sample, and episodic and semantic memory performance was operationalized as the mean of the two respective task measures. The distributions of the mean episodic and semantic memory z-scores were negatively skewed ( $D(172)=1.0, p < .001$  and  $D(172)=1.0, p < .001$ , respectively). Normality of distribution is not a prerequisite in linear regression with sufficiently large sample sizes provided that the residuals are normally distributed and homoscedastic, i.e., that their variance does not vary as a function of the predicted variable (Lumley, Diehr, Emerson, & Chen, 2002). Therefore, to ensure the validity of the brain-behavior analyses, we conducted four regression analyses where the mean semantic memory z-score and mean episodic memory z-score were used to predict the mean signal intensity in each ROI and examined their residuals. Shapiro-Wilk tests indicated that none of the four sets of residuals statistically differed from a normal distribution (all  $D(172) > 0.9$ , all  $p > 0.4$ ). Moreover, an examination of the residuals plotted against the predicted values confirmed that these data were homoscedastic. Taken together, these analyses demonstrate the validity of the planned linear regression analyses of the ROI data.

#### 2.4.3. Fractional anisotropy (FA) analyses

**2.4.3.1. Preprocessing of DTI volumes.** The preprocessing of DTI volumes was performed using FMRIB (analysis group at the Oxford Center for Functional MRI of the Brain) software library tools (FSL v4.1.6; <http://www.fmrib.ox.ac.uk/fsl>). Using FMRIB's diffusion toolbox (FDT v2.0), diffusion volumes were corrected for eddy currents and simple motion using affine registration to a single  $b_0$  image of the same participant. The two DTI sets from the same participant were then averaged, and a brain mask of the averaged  $b_0$ s was generated using the brain extraction tool BET v2.1 (Smith, 2002). Finally, diffusion tensors were fit to the data and resulting FA values were used for further analyses. FA values carry information about fiber orientation, where high FA values correspond to highly organized WM tracts and low FA values to disorganized tracts, i.e., a purported breakdown of WM (Medina et al., 2006; Stamatakis, Shafto, Williams, Tam, & Tyler, 2011).

Seven participants were excluded from the DTI analyses for the following reasons: DTI data described above were not available for three participants (one NC and two aMCI patients), and data from four NC participants failed preprocessing due to an error during image acquisition. Statistical analyses revealed no significant differences in the demographic characteristics (age, education, gender) or MMSE scores between the excluded ( $n=7$ ) and included subjects ( $n=165$ ) (age:  $U=396, z=-1.4, p > 0.2$ ; education:  $U=478, z=-0.8, p > 0.4$ ; gender distribution:  $\chi^2 > 0.3, p > 0.7$ ; MMSE:  $U=483, z=-0.8, p > 0.5$ ). Furthermore, there were no differences in the demographic characteristics and MMSE scores of participants included in the VBM and DTI analyses (all  $T > -0.2$ , all  $p=1.0$ ; for gender distribution:  $\chi^2 > 0.01, p > 0.9$ ).

**2.4.3.2. Spatial normalization of FA images.** The preprocessing of the FA images was performed in SPM8 (Wellcome Institute of Cognitive Neurology, [www.fil.ion.ucl.ac.uk](http://www.fil.ion.ucl.ac.uk)) implemented in Matlab 2010 (Mathworks Inc., Sherborn, MA, USA). The average  $b_0$  of each subject was first linearly and nonlinearly coregistered to the MNI EPI template of SPM8, and the resulting transformations were applied to the corresponding FA image. The resulting normalized FA images were then visually inspected to ensure satisfactory transformation into standard space and smoothed with a 10 mm FWHM Gaussian kernel.

**2.4.3.3. FA voxel-based morphometry analyses.** A first set of analyses comprised two independent whole-brain regression analyses where participants' individual performance scores on (a) episodic (CVLT and ROCF) and (b) semantic (BNT and CVFA) memory tasks were correlated with FA signal intensities at each voxel across all brains. A second analysis tested for the unique relationship between episodic memory performance and FA indices while controlling for the effect of semantic memory performance, and vice versa. This regression analysis included all four episodic and semantic memory measures in a single model. All analyses with FA included age and WM volume as covariates, thereby controlling for age-related effects and effects due to a combination of overall level of WM atrophy and head size.

All analyses were masked with a whole brain white matter mask from the WFU Pick Atlas V.3.0.3 (Maldjian, Laurienti, Kraft, & Burdette, 2003; Stamatakis et al., 2011). The statistical parametric maps were thresholded at  $p < 0.01$  uncorrected at the voxel level and clusters surviving a random field corrected  $p < 0.05$  are

reported in MNI space. The JHU tractography atlas tool in FSLVIEW of FSL (<http://www.fmrib.ox.ac.uk/fsl/>) was used to identify major WM tracts, and the Harvard-Oxford subcortical structural atlas in FSLVIEW provided regional WM labels. Because the focus of this study is the aMTL, only significant correlations between FA values and behavioral performance measures within this anatomical region are described in the main text, while a full description of significant clusters is provided in Table 2 and Supplementary Fig. 1.

## 3. Results

### 3.1. Behavioral Results

To determine whether NC, aMCI and AD patients groups differed with respect to their episodic and semantic neuropsychological test performance, one-way independent ANOVAs or Kruskal-Wallis tests were conducted on individual CVFA and on CVLT, ROCF and BNT scores, respectively. These analyses revealed significant main effects of diagnostic group on performance on both episodic (CVLT and ROCF) and both semantic (CVFA and BNT) memory tests (see Table 1), as expected. *Post-hoc* tests revealed that the NC participants performed significantly better than aMCI patients, who performed significantly better than AD patients on the CVLT ( $U=414.0, p < 0.001$  and  $U=64, p=0.004$ , respectively), ROCF ( $U=987.5, p < 0.001$  and  $U=59.5, p=0.003$ , respectively), and CVFA ( $t(160)=-3.4, p=0.001$  and  $t(40)=-3.0, p=0.005$ ). NC participants named significantly more BNT pictures correctly than the AD and aMCI patients ( $U=266.5, p < 0.01$  and  $U=1077.5, p < 0.001$ , respectively), but the performance of aMCI and AD patients did not differ ( $U=150.5, p=0.8$ ). Group differences were also found on the mean episodic and semantic memory z-scores (see Table 1). *Post-hoc* tests revealed that mean episodic and semantic memory z-scores were significantly higher in the NC participants than aMCI and AD patients (episodic memory:  $U=400.5, p < 0.001$  and  $U=14.0, p < 0.001$ , respectively; semantic memory:  $U=1040.5, p < 0.001$  and  $U=79, p < 0.001$ , respectively). aMCI and AD patients also obtained significantly different mean episodic ( $U=36.0, p < 0.001$ ) but not mean semantic memory z-scores ( $U=109.0, p < 0.1$ ).

### 3.2. Imaging analyses

#### 3.2.1. General functional neuroanatomical correlates of episodic and semantic memory performance

**3.2.1.1. Episodic memory performance.** Linear regression analyses were used to predict mean signal intensities in the left and right ERC/HP head and mPRC ROIs of each participant. Since this analysis did not control for semantic memory performance, its results reflect the general relationship between episodic memory performance and GM integrity in each ROI, i.e., including potential support from semantic memory processes. Episodic memory performance significantly predicted mean signal intensity in the left ERC/HP head ( $\beta=0.342, t(171)=5.101, p < 0.001$ ) and left mPRC ( $\beta=0.218, t(171)=3.117, p=0.002$ ). The same pattern was found for the right hemisphere ROIs (ERC/HP head:  $\beta=0.314, t(171)=4.727, p < 0.001$  and mPRC:  $\beta=0.230, t(171)=3.313, p=0.001$ ).

Independent whole-brain voxel-based correlation analyses with FA volumes revealed that episodic memory measures correlated with WM surrounding the bilateral ERC/HP and amygdala, as well as parts of the uncinate fasciculus and left temporal pole WM (see Fig. 1 and Table 2).

**3.2.1.2. Semantic memory performance.** Analogous ROI analyses revealed that semantic memory performance significantly correlated with both the left and right mPRC ( $\beta=0.288, t(171)=4.143, p < 0.001$  and  $\beta=0.227, t(171)=3.219, p=0.002$ , respectively)

**Table 2**  
Results of voxel-based correlational analyses with FA volumes for each memory performance independently (A) and while controlling for the contrasting type of memory performance (B).

Cluster-level		Voxel-level		Coordinates of peak voxel		
$p_{\text{corrected}}^a$	Extent <sup>b</sup>	$t$ -score	$p_{\text{corrected}}^c$	x	y	z
<b>A</b>						
<b>Episodic memory performance (CVLT<sup>d</sup> and ROCF<sup>e</sup>)</b>						
0.000	11152	5.7	0.001	28	0	–14
		4.8	0.049	16	–38	8
		4.7	0.069	–32	–4	–12
Regions in cluster: Genu of corpus callosum (including forceps minor), body and splenium of corpus callosum (including forceps major), bilateral anterior thalamic radiation (anterior part), posterior thalamic radiation (include optic radiation), anterior limb of the internal capsule, posterior limb of the internal capsule, anterior, posterior, and superior corona radiata, uncinate fasciculus (anterior aspects), inferior fronto-occipital fasciculus (anterior and posterior aspects), cingulum hippocampal part (posterior aspects), cingulum (posterior aspects), corticospinal tract, inferior longitudinal fasciculus (posterior aspects)						
<b>Semantic memory performance (BVL<sup>f</sup> and CVFA<sup>g</sup>)</b>						
0.004	3585	4.0	0.520	18	26	32
		3.9	0.640	20	–4	38
		3.8	0.785	18	14	38
Regions in cluster: Genu of corpus callosum (including forceps minor), body and splenium of corpus callosum (including forceps major), right anterior limb of internal capsule, posterior limb of internal capsule, anterior and posterior corona radiata, inferior fronto-occipital fasciculus (anterior aspects), cingulum (posterior aspects), corticospinal tract						
0.002	3973	4.0	0.558	–28	–4	–8
		4.0	0.605	–20	–42	32
		3.8	0.725	–26	6	38
Regions in cluster: Genu of corpus callosum (including forceps minor), body and splenium of corpus callosum (including forceps major), bilateral anterior thalamic radiata, left anterior and posterior limb of internal capsule, anterior, superior and posterior corona radiata, inferior fronto-occipital fasciculus (anterior aspects), inferior longitudinal fasciculus (anterior part), cingulum (posterior aspects), corticospinal tract, superior longitudinal fasciculus						
<b>B</b>						
<b>Episodic memory performance (CVLT<sup>d</sup> and ROCF<sup>e</sup>) controlling for semantic memory performance</b>						
0.002	4013	4.4	0.183	28	0	–14
		3.9	0.692	–28	42	–14
		3.7	0.871	–4	–34	18
Regions in cluster: Genu of corpus callosum (including forceps minor), body and splenium of corpus callosum (including forceps major), bilateral anterior limb of internal capsule, external capsule, anterior thalamic radiation, left posterior limb of internal capsule, anterior corona radiata, right superior and posterior corona radiata, uncinate fasciculus						
<b>Semantic memory performance (BVL<sup>f</sup> and CVFA<sup>g</sup>) controlling for episodic memory performance</b>						
Regions in cluster: No significant clusters						

<sup>a</sup> Cluster-level  $p$ -value corrected for search volume.

<sup>b</sup> Number of voxels in cluster.

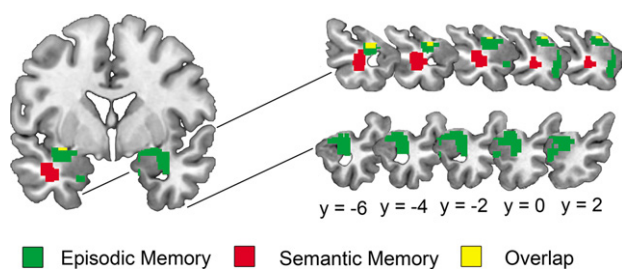
<sup>c</sup> Voxel-level  $p$ -value corrected for search volume.

<sup>d</sup> CVLT=German version of the California Verbal Learning Test, Long Delay Free recall (Delis et al., 1987).

<sup>e</sup> ROCF=Rey-Osterrieth Complex Figure, Long Delay Free Recall (Osterrieth, 1944).

<sup>f</sup> CVFA=Category Verbal Fluency Animals (Morris et al., 1989) in 1 min.

<sup>g</sup> BNT=short, 15-item version of the Boston Naming Test (Morris et al., 1989).



**Fig. 1.** Representative slices showing aMTL regions where FA voxel values significantly correlated with episodic and semantic memory performance in independent voxel-based regression analyses. (MNI coordinates are reported).

and ERC/HP head ( $\beta=0.374$ ,  $t(171)=5.588$ ,  $p < 0.001$  and  $\beta=0.340$ ,  $t(171)=5.114$ ,  $p < 0.001$ , respectively).

An independent whole-brain voxel-based correlation analysis with FA volumes revealed that semantic memory measures correlated with the left anterior inferior longitudinal fasciculus (aILF), which provides the primary input to the PRC (see Fig. 1 and Table 2).

Thus, independent GM ROI analyses revealed that both episodic and semantic memory performance was associated with the integrity of the same GM structures, i.e., bilateral ERC/HP head and mPRC. In contrast, independent FA regression analyses indicated different patterns of WM involvement in episodic and semantic memory functioning, with episodic memory performance correlating with the integrity of WM surrounding bilateral ERC/HP, including the uncinate fasciculus, and semantic memory performance significantly related to the integrity of the anterior part of the left inferior longitudinal fasciculus.

### 3.2.2. Functional neuroanatomical relationships of episodic and semantic memory performance while controlling for the contrasting memory performance

**3.2.2.1. Episodic memory performance.** ROI analyses controlling for the effect of semantic memory performance revealed that episodic memory performance significantly predicted with mean signal

intensity of the left ( $\beta=0.202$ ,  $t(171)=2.622$ ,  $p=0.01$ ) and the right ERC/HP head ( $\beta=0.187$ ,  $t(171)=2.445$ ,  $p<0.05$ ). Importantly, episodic memory performance did not significantly predict mean signal intensity of the left ( $\beta=0.093$ ,  $t(171)=1.141$ ,  $p=0.256$ ) or the right mPRC ( $\beta=0.154$ ,  $t(171)=1.890$ ,  $p=0.061$ ).

The unique whole-brain regression analysis with FA volumes revealed one cluster of voxels centered in the right amygdala (28, 0, -14) extending into the WM surrounding the bilateral ERC and HP (see Table 3).

**3.2.2.2. Semantic memory performance.** ROI analyses revealed that when the effect of episodic memory performance was controlled, semantic memory performance significantly predicted mean signal intensities in both the left mPRC ( $\beta=0.237$ ,  $t(171)=2.891$ ,  $p=0.004$ ) and ERC/HP head ( $\beta=0.264$ ,  $t(171)=3.397$ ,  $p=0.001$ ). Within the right hemisphere, semantic memory performance significantly mean signal intensities of the ERC/HP head ( $\beta=0.238$ ,  $t(171)=3.073$ ,  $p=0.002$ ) but not the right mPRC ( $\beta=0.143$ ,  $t(171)=1.727$ ,  $p=0.086$ ).

The unique whole-brain analysis with FA volumes revealed no significant results. Given our *a priori* hypothesis for a unique relationship between FA volumes and aILF integrity, we calculated a small volume correction with the aILF portion of the FA cluster found in the independent analysis (JHU tractography atlas tool in FSLVIEW of FSL; <http://www.fmrib.ox.ac.uk/fsl/>). With this small volume correction, aILF FA values significantly correlated with unique aspects of semantic processing (corrected cluster-level  $p=0.05$ ).

#### 4. Discussion

The present results indicate that a functional differentiation within the aMTL can be assessed with commonly used clinical tests if the shared variance between episodic and semantic memory measures is accounted for. Specifically, unique *a priori* ROI analyses demonstrated that episodic memory performance was associated with the bilateral ERC/HP head but not with the left or right mPRC. In contrast, semantic memory performance was associated with left mPRC and bilateral ERC/HP head integrity. These findings support established models of episodic memory functioning (Eichenbaum et al., 1999; Lipton & Eichenbaum, 2008), and are consistent with a relatively recent account of semantic object memory (Murray et al., 1998; Murray & Richmond, 2001; Taylor et al., 2006, 2009, 2011; Tyler et al., 2004).

Clinical tests of episodic and semantic memory rely on non-mnemonic cognitive processes such as attention and executive functioning (Lezak et al., 2004), as well as processes related to stimulus modality (e.g., verbal, visuospatial functions). Furthermore, episodic memory performance may be facilitated by semantic memory processes and vice versa (Greenberg et al., 2009; Greenberg & Verfaellie, 2010). Therefore, task performance necessarily reflects the influence of many brain networks, complicating the interpretation of neuropsychological test scores. This issue is illustrated by the high degree of overlap of the clusters in the independent VBM analyses. To account for the influences of the shared non-mnemonic and mnemonic processes, we examined one type of memory performance while controlling for the other. As expected, these unique analyses revealed a more specific functional-neuroanatomy of episodic and semantic performance compared to the uncontrolled, independent analyses. Thus, this approach may be useful in the clinical neuropsychological setting to obtain more “process pure” measures.

The present finding of a unique relationship between episodic memory performance and the neural integrity of the bilateral ERC/HP is consistent with previous studies demonstrating that

ERC/HP atrophy predicts poor episodic memory performance (Acosta-Cabrero, Williams, Pengas, & Nestor, 2010; de Toledo-Morrell, Goncharova, Dickerson, Wilson, & Bennett, 2000; de Toledo-Morrell et al., 2000; Killiany et al., 2002; Kramer et al., 2004). Furthermore, we found that poor episodic memory performance was associated with decreased integrity of the WM surrounding the bilateral ERC/HP in the independent as well as unique analyses. The affected aMTL areas included aspects of the uncinate fasciculus, which has been associated with episodic memory performance in temporal lobe epilepsy and schizophrenic patients (Diehl et al., 2008; Nestor et al., 2004; Nestor et al., 2008). Thus, these results indicate that in AD, disconnection of aMTL structures (such as the ERC/HP) from incoming information may contribute to episodic memory impairments. Taken together, the present findings suggest that reduced GM integrity of the ERC/HP and its surrounding WM underpins episodic memory impairments in the AD syndrome.

The unique association between poor semantic memory performance and left mPRC damage is in line with previous experimental studies in brain-damaged patients (Moss, Rodd, Stamatakis, Bright, & Tyler, 2005; Taylor et al., 2009; Tyler et al., 2004) as well as studies using clinical neuropsychological tasks in semantic dementia patients (Davies et al., 2004; Desgranges et al., 2007). In particular, Kivisaari, Tyler, Monsch, and Taylor (2012) demonstrated that the mPRC, but not the surrounding aMTL regions, is necessary for identifying semantically confusable concepts in very early AD patients. Taken together with the present results, these studies demonstrate that it is possible to detect specific relationships between semantic memory performance and the PRC, as opposed to the entire MTL, and argue against the notion that PRC brain damage is simply a proxy for MTL damage (Levy, Bayley, & Squire, 2004). Although the current study found that atrophy in both the PRC and ERC/HP was associated with poor semantic memory performance, previous studies suggest that isolated PRC damage may be sufficient to induce semantic memory impairments. Specifically, semantic memory performance was relatively preserved in patients with bilateral HP damage and severe impairments in episodic memory (Mayes, Holdstock, Isaac, Hunkin, & Roberts, 2002; Vargha-Khadem et al., 1997).

The independent and unique small volume corrected FA analyses revealed that semantic memory impairments were also associated with decreased FA values in the anterior part of the inferior longitudinal fasciculus which connects the occipital lobe with the anterior temporal lobe and which represents the primary input to the PRC (Catani & Thiebaut de Schotten, 2008; Murray & Richmond, 2001). The finding that the aILF is especially important for semantic memory is consistent with other studies that reported decreased FA values in the aILF in patients with semantic deficits (Agosta et al., 2010; Galantucci et al., 2011). Taken together, in the context of AD, these results suggest that reduced GM integrity of the PRC and reduced WM integrity of its main input stream (i.e., the aILF) are associated with semantic memory dysfunction. Importantly, the present findings further demonstrate that clinical neuropsychological measures of semantic memory are specifically sensitive to mPRC GM damage when episodic memory performance is controlled.

Other authors argue that lateral, but not medial regions of the anterior temporal lobe are critical for semantic abilities (Levy et al., 2004; Patterson, Nestor, & Rogers, 2007). For example, a lesion-symptom correlation study and a voxel-based morphometry study in semantic dementia (SD) patients showed that the left temporal pole and inferior lateral temporal areas, but not the PRC, significantly correlated with semantic performance. The present study did not test the relationship between inferolateral temporal lobe integrity and semantic memory performance. However, contrary to the alternative account of semantic memory, the present findings do suggest that anterior lateral temporal lobe damage is not necessary, and that aMTL damage is sufficient, to induce semantic memory impairments.

Taken together, the present findings are consistent with the view that different aMTL structures perform partially different kinds of memory functions (Bussey & Saksida, 2002; Kivisaari et al., in press; Lavenex & Amaral, 2000; Mishkin, Suzuki, Gadian, & Vargha-Khadem, 1997; Murray, Bussey, & Saksida, 2007). This functional specialization account stems from non-human primate studies implicating rich afferent connectivity from the visual object processing stream, as well as less dense uni- and polymodal inputs to the PRC (Suzuki, 1996; Suzuki & Amaral, 1994). These connections putatively render the PRC both necessary and sufficient for semantic and multimodal processing of individual objects (Lavenex & Amaral, 2000; Murray et al., 1998; Taylor et al., 2006; Vargha-Khadem et al., 1997). This model accounts for the present findings that poor semantic memory performance was associated with reduced left mPRC volume and a breakdown of its WM afferents. The PRC in turn projects to the ERC, where the object information is bound to its spatial context and other higher-order information (Lavenex & Amaral, 2000; Mishkin et al., 1997; Suzuki, 1996), and on to the HP, which represents the culmination of the “hierarchical model of connectivity” (Lavenex & Amaral, 2000). On this account, the ERC/HP are specialized for processing objects in their wider associational, spatial and temporal context and, by doing so, give rise to episodic memories (Eichenbaum et al., 1999; Lavenex & Amaral, 2000; Lipton & Eichenbaum, 2008; Mishkin et al., 1997). Consistent with this view, episodic memory performance was associated mainly with reduced GM and WM integrity of bilateral ERC/HP.

The functional specialization account generates novel hypotheses about how clinicians could assess the earliest cognitive changes associated with AD. Specifically, since neurofibrillary pathology in AD begins in the mPRC before entering the ERC/HP (Braak & Braak, 1991; Taylor & Probst, 2008), this model suggests that impairments in semantic object memories may occur in the earliest stages of AD (see e.g., Amieva et al., 2008). The findings from the present study demonstrate that measures from commonly used neuropsychological tests of semantic (object) memory, when controlled for episodic memory processes, are capable of estimating the integrity of the cortical region affected earliest by neurofibrillary AD pathology, the mPRC.

## Acknowledgements

This study was financed by the Alzheimer's Association of both Basels, the Foundation for Dementia Research Basel, an Ambizione Fellowship from the Swiss National Science Foundation (KIT), a Tilma Hainari Jubilee Grant from the Finnish Concordia Fund and the Swiss Federal Commission for Scholarships for Foreign Students (Berne) (SLK). MRI scanning was financed by research grants from the Novartis Foundation and GlaxoSmithKline (AUM).

The funding sources had no involvement in study design, in the collection, analysis and interpretation of data.

## Appendix A. Supporting information

Supplementary data associated with this article can be found in the online version at <http://dx.doi.org/10.1016/j.neuropsychologia.2013.01.013>.

## References

- Acosta-Cabrero, J., Williams, G. B., Pengas, G., & Nestor, P. J. (2010). Absolute diffusivities define the landscape of white matter degeneration in Alzheimer's disease. *Brain*, *133*(2), 529–539, <http://dx.doi.org/10.1093/brain/awp257>.
- Agosta, F., Henry, R. G., Migliaccio, R., Neuhaus, J., Miller, B. L., Dronkers, N. F., et al. (2010). Language networks in semantic dementia. *Brain*, *133*(1), 286–299, <http://dx.doi.org/10.1093/brain/awp233>.
- American Psychiatric Association (1994). *DSM-IV: Diagnostics and Statistical Manual of Mental Disorders*. Washington, DC: Author.
- Amieva, H., Le Goff, M., Millet, X., Orgogozo, J. M., Pérès, K., Barberger-Gateau, P., et al. (2008). Prodromal Alzheimer's disease: successive emergence of the clinical symptoms. *Annals of Neurology*, *64*(5), 492–498, <http://dx.doi.org/10.1002/ana.21509>.
- Ashburner, J. (2007). A fast diffeomorphic image registration algorithm. *NeuroImage*, *38*(1), 95–113, <http://dx.doi.org/10.1016/j.neuroimage.2007.07.007>.
- Braak, H., & Braak, E. (1991). Neuropathological staging of Alzheimer-related changes. *Acta Neuropathologica*, *82*(4), 239–259, <http://dx.doi.org/10.1007/BF00308809>.
- Braak, H., & Braak, E. (1995). Staging of Alzheimer's disease-related neurofibrillary changes. *Neurobiology of Aging*, *16*(3), 271–278, [http://dx.doi.org/10.1016/0197-4580\(95\)00021-6](http://dx.doi.org/10.1016/0197-4580(95)00021-6).
- Buschke, H., & Fuld, P. A. (1974). Evaluating storage, retention, and retrieval in disordered memory and learning. *Neurology*, *24*(11), 1019–1025.
- Bussey, T. J., & Saksida, L. M. (2002). The organization of visual object representations: a connectionist model of effects of lesions in perirhinal cortex. *European Journal of Neuroscience*, *15*(2), 355–364, <http://dx.doi.org/10.1046/j.0953-816x.2001.01850.x>.
- Catani, M., & Thiebaut de Schotten, M. (2008). A diffusion tensor imaging tractography atlas for virtual in vivo dissections. *Cortex*, *44*(8), 1105–1132, <http://dx.doi.org/10.1016/j.cortex.2008.05.004>.
- Davies, R. R., Graham, K. S., Xuereb, J. H., Williams, G. B., & Hodges, J. R. (2004). The human perirhinal cortex and semantic memory. *European Journal of Neuroscience*, *20*(9), 2441–2446, <http://dx.doi.org/10.1111/j.1460-9568.2004.03710.x>.
- de Toledo-Morrell, L., Goncharova, I., Dickerson, B., Wilson, R. S., & Bennett, D.A. (2000). From healthy aging to early Alzheimer's disease: in vivo detection of entorhinal cortex atrophy. *Annals of the New York Academy of Sciences*, *911*(1), 240–253, <http://dx.doi.org/10.1111/j.1749-6632.2000.tb06730.x>.
- de Toledo-Morrell, L., Dickerson, B., Sullivan, M. P., Spanovic, C., Wilson, R., & Bennett, D. A. (2000). Hemispheric differences in hippocampal volume predict verbal and spatial memory performance in patients with Alzheimer's disease. *Hippocampus*, *10*(2), 136–142, [http://dx.doi.org/10.1002/\(SICI\)1098-1063\(2000\)10:2<136::AID-HIPO2>3.0.CO;2-J](http://dx.doi.org/10.1002/(SICI)1098-1063(2000)10:2<136::AID-HIPO2>3.0.CO;2-J).
- Delis, D. C., Kramer, J. H., & Ober, B. A. (1987). *California Verbal Learning Test*. San Antonio, TX: Psychological Corporation.
- Desgranges, B., Matuszewski, V., Piolino, P., Chételat, G., Mézange, F., Landeau, B., et al. (2007). Anatomical and functional alterations in semantic dementia: a voxel-based MRI and PET study. *Neurobiology of Aging*, *28*(12), 1904–1913, <http://dx.doi.org/10.1016/j.neurobiolaging.2006.08.006>.
- Diehl, B., Busch, R. M., Duncan, J. S., Piao, Z., Tkach, J., & Lüders, H. O. (2008). Abnormalities in diffusion tensor imaging of the uncinate fasciculus relate to reduced memory in temporal lobe epilepsy. *Epilepsia*, *49*(8), 1409–1418, <http://dx.doi.org/10.1111/j.1528-1167.2008.01596.x>.
- Eichenbaum, H., Dudchenko, P., Wood, E., Shapiro, M., & Tanila, H. (1999). The hippocampus, memory, and place cells: is it spatial memory or a memory space? *Neuron*, *23*(2), 209–226, [http://dx.doi.org/10.1016/S0896-6273\(00\)80773-4](http://dx.doi.org/10.1016/S0896-6273(00)80773-4).
- Folstein, M. F., Folstein, S. E., & McHugh, P. R. (1975). “Mini-mental state”: a practical method for grading the cognitive state of patients for the clinician. *Journal of Psychiatric Research*, *12*(3), 189–198, [http://dx.doi.org/10.1016/0022-3956\(75\)90026-6](http://dx.doi.org/10.1016/0022-3956(75)90026-6).
- Galantucci, S., Tartaglia, M. C., Wilson, S. M., Henry, M. L., Filippi, M., Agosta, F., et al. (2011). White matter damage in primary progressive aphasia: a diffusion tensor tractography study. *Brain*, *134*(10), 3011–3029, <http://dx.doi.org/10.1093/brain/awr099>.
- Gertz, H. J., Xuereb, J., Huppert, F., Brayne, C., McGee, M. A., Paykel, E., et al. (1998). Examination of the validity of the hierarchical model of neuropathological staging in normal aging and Alzheimer's disease. *Acta Neuropathologica*, *95*(2), 154–158, <http://dx.doi.org/10.1007/s004010050780>.
- Greenberg, D. L., Keane, M. M., Ryan, L., & Verfaellie, M. (2009). Impaired category fluency in medial temporal lobe amnesia: the role of episodic memory. *The Journal of Neuroscience*, *29*(35), 10900–10908, <http://dx.doi.org/10.1523/JNEUROSCI.1202-09.2009>.
- Greenberg, D. L., & Verfaellie, M. (2010). Interdependence of episodic and semantic memory: evidence from neuropsychology. *Journal of the International Neuropsychological Society*, *16*(05), 748–753, <http://dx.doi.org/10.1017/S1355617710000676>.
- Hodges, J. R., Salmon, D. P., & Butters, N. (1992). Semantic memory impairment in Alzheimer's disease: failure of access or degraded knowledge? *Neuropsychologia*, *30*(4), 301–314, [http://dx.doi.org/10.1016/0028-3932\(92\)90104-T](http://dx.doi.org/10.1016/0028-3932(92)90104-T).
- Kaplan, E., Goodglass, H., Weintraub, S., & Segal, O. (1983). *Boston Naming Test*. Philadelphia: Lea & Febiger.
- Killiany, R. J., Hyman, B. T., Gomez-Isla, T., Moss, M. B., Kikinis, R., Jolesz, F., et al. (2002). MRI measures of entorhinal cortex vs. hippocampus in preclinical AD. *Neurology*, *58*(8), 1188–1196.
- Kivisaari, S. L., Probst, A., & Taylor, K. I. (in press). The perirhinal, entorhinal and parahippocampal cortices and hippocampus: An overview of functional anatomy and a protocol for their segmentation in MR images. In: S. Ulmer & O. Jansen (Eds.), *fMRI-basics and clinical applications*, (2nd ed.). Berlin Heidelberg: Springer Verlag.
- Kivisaari, S. L., Tyler, L. K., Monsch, A. U., & Taylor, K. I. (2012). Medial perirhinal cortex disambiguates confusable objects. *Brain*, *135*, 3757–3769.
- Kramer, J. H., Schuff, N., Reed, B. R., Mungas, D., Du, A.-T., Rosen, H. J., et al. (2004). Hippocampal volume and retention in Alzheimer's disease. *Journal of the*

- International Neuropsychological Society*, 10(04), 639–643, <http://dx.doi.org/10.1017/S1355617704104050>.
- Lavenex, P., & Amaral, D. G. (2000). Hippocampal-neocortical interaction: a hierarchy of associativity. *Hippocampus*, 10(4), 420–430, [http://dx.doi.org/10.1002/1098-1063\(2000\)10:4<420::AID-HIPO8>3.0.CO;2-5](http://dx.doi.org/10.1002/1098-1063(2000)10:4<420::AID-HIPO8>3.0.CO;2-5).
- Levy, D. A., Bayley, P. J., & Squire, L. R. (2004). The anatomy of semantic knowledge: medial vs. lateral temporal lobe. *Proceedings of the National Academy of Sciences of the United States of America*, 101(17), 6710–6715, <http://dx.doi.org/10.1073/pnas.0401679101>.
- Lezak, M. D., Howieson, D. B., Loring, D. W., Hannay, H. J., & Fischer, J. S. (2004). *Neuropsychological Assessment* (4th ed.). New York, NY: Oxford University Press.
- Lipton, P. A., & Eichenbaum, H. (2008). Complementary roles of hippocampus and medial entorhinal cortex in episodic memory. *Neural Plasticity*, 2008, 1–8, <http://dx.doi.org/10.1155/2008/258467>.
- Lumley, T., Diehr, P., Emerson, S., & Chen, L. (2002). The importance of the normality assumption in large public health data sets. *Annual Review of Public Health*, 23(1), 151–169, <http://dx.doi.org/10.1146/annurev.publhealth.23.100901.140546>.
- Maldjian, J. A., Laurienti, P. J., Kraft, R. A., & Burdette, J. H. (2003). An automated method for neuroanatomic and cytoarchitectonic atlas-based interrogation of fMRI data sets. *NeuroImage*, 19(3), 1233–1239, [http://dx.doi.org/10.1016/S1053-8119\(03\)00169-1](http://dx.doi.org/10.1016/S1053-8119(03)00169-1).
- Mayes, A. R., Holdstock, J. S., Isaac, C. L., Hunkin, N. M., & Roberts, N. (2002). Relative sparing of item recognition memory in a patient with adult-onset damage limited to the hippocampus. *Hippocampus*, 12(3), 325–340, <http://dx.doi.org/10.1002/hipo.1111>.
- McKhann, G., Drachman, D., Folstein, M., Katzman, R., Price, D., & Stadlan, E. M. (1984). Clinical diagnosis of Alzheimer's disease: report of the NINCDS-ADRDA work group under the auspices of Department of Health and Human Services task force on Alzheimer's disease. *Neurology*, 34(7), 939–944.
- Medina, D., deTolledo-Morrell, L., Urresta, F., Gabrieli, J. D. E., Moseley, M., Fleischman, D., et al. (2006). White matter changes in mild cognitive impairment and AD: a diffusion tensor imaging study. *Neurobiology of Aging*, 27(5), 663–672, <http://dx.doi.org/10.1016/j.neurobiolaging.2005.03.026>.
- Mishkin, M., Suzuki, W. A., Gadian, D. G., & Vargha-Khadem, F. (1997). Hierarchical organization of cognitive memory. *Philosophical Transactions of the Royal Society B: Biological Sciences*, 352(1360), 1461–1467.
- Monsch, A. U., Thalmann, B., Schneitter, M., Bernasconi, F., Aebi, C., Camachova-Davet, Z., et al. (2000). The Basel study on the elderly's search for preclinical cognitive markers of Alzheimer's disease. *Neurobiology of Aging*, 1(0), 31, [http://dx.doi.org/10.1016/S0197-4580\(00\)82817-1](http://dx.doi.org/10.1016/S0197-4580(00)82817-1). Supplement.
- Morris, J. C., Heyman, A., Mohs, R. C., Hughes, J. P., van Belle, G., Fillenbaum, G., et al. (1989). The Consortium to Establish a Registry for Alzheimer's Disease (CERAD). Part I. Clinical and neuropsychological assessment of Alzheimer's disease. *Neurology*, 39, 1159–1165.
- Moss, H. E., Rodd, J. M., Stamatakis, E. A., Bright, P., & Tyler, L. K. (2005). Anteromedial temporal cortex supports fine-grained differentiation among objects. *Cerebral Cortex*, 15(5), 616–627, <http://dx.doi.org/10.1093/cercor/bhh163>.
- Murray, E. A., Bussey, T. J., & Saksida, L. M. (2007). Visual perception and memory: a new view of medial temporal lobe function in primates and rodents. *Annual Review of Neuroscience*, 30(1), 99–122, <http://dx.doi.org/10.1146/annurev.neuro.29.051605.113046>.
- Murray, E.A., Malkova, L., & Goulet, S. (1998). Crossmodal associations, intramodal associations, and object identification in macaque monkeys. In: A. D. Milner (Ed.), *Comparative neuropsychology*. Oxford: Oxford University Press pp. 51–69.
- Murray, E. A., & Richmond, B. J. (2001). Role of perirhinal cortex in object perception, memory, and associations. *Current Opinion in Neurobiology*, 11(2), 188–193, [http://dx.doi.org/10.1016/S0959-4388\(00\)00195-1](http://dx.doi.org/10.1016/S0959-4388(00)00195-1).
- Nestor, P. G., Kubicki, M., Gurrera, R. J., Niznikiewicz, M., Frumin, M., McCarley, R. W., et al. (2004). Neuropsychological correlates of diffusion tensor imaging in schizophrenia. *Neuropsychology*, 18(4), 629–637, <http://dx.doi.org/10.1037/0894-4105.18.4.629>.
- Nestor, P. G., Kubicki, M., Niznikiewicz, M., Gurrera, R. J., McCarley, R. W., & Shenton, M. E. (2008). Neuropsychological disturbance in schizophrenia: a diffusion tensor imaging study. *Neuropsychology*, 22(2), 246–254, <http://dx.doi.org/10.1037/0894-4105.22.2.246>.
- Osterrieth, P. A. (1944). Le test de copie d'une figure complexe; contribution à l'étude de la perception et de la mémoire. [Test of copying a complex figure; contribution to the study of perception and memory.]. *Archives de Psychologie*, 30, 206–356.
- Parker, A., & Gaffan, D. (1998). Lesions of the primate rhinal cortex cause deficits in flavour–visual associative memory. *Behavioural Brain Research*, 93(1–2), 99–105, [http://dx.doi.org/10.1016/S0166-4328\(97\)00148-4](http://dx.doi.org/10.1016/S0166-4328(97)00148-4).
- Patterson, K., Nestor, P. J., & Rogers, T. T. (2007). Where do you know what you know? The representation of semantic knowledge in the human brain. *Nature Reviews Neuroscience*, 8(12), 976–987, <http://dx.doi.org/10.1038/nrn2277>.
- Petersen, R. C. (2004). Mild cognitive impairment as a diagnostic entity. *Journal of Internal Medicine*, 256(3), 183–194, <http://dx.doi.org/10.1111/j.1365-2796.2004.01388.x>.
- Petersen, R. C., Jack, C. R., Xu, Y. C., Waring, S. C., O'Brien, P. C., Smith, G. E., et al. (2000). Memory and MRI-based hippocampal volumes in aging and AD. *Neurology*, 54, 3.
- Ryan, L., Cox, C., Hayes, S. M., & Nadel, L. (2008). Hippocampal activation during episodic and semantic memory retrieval: comparing category production and category cued recall. *Neuropsychologia*, 46(8), 2109–2121, <http://dx.doi.org/10.1016/j.neuropsychologia.2008.02.030>.
- Salmon, D. P. (2011). Neuropsychological features of mild cognitive impairment and preclinical Alzheimer's disease. *Current Topics in Behavioral Neurosciences*, 10, 121–187 doi: 10.1007/7854\_2011\_171.
- Salmon, D. P., & Bondi, M. W. (2008). Neuropsychological assessment of dementia. *Annual Review of Psychology*, 60(1), 257–282, <http://dx.doi.org/10.1146/annurev.psych.57.102904.190024>.
- Saxton, J., Lopez, O. L., Ratcliff, G., Dulberg, C., Fried, L. P., Carlson, M. C., et al. (2004). Preclinical Alzheimer disease. *Neurology*, 63(12), 2341–2347.
- Smith, S. M. (2002). Fast robust automated brain extraction. *Human Brain Mapping*, 17(3), 143–155, <http://dx.doi.org/10.1002/hbm.10062>.
- Stamatakis, E. A., Shafto, M. A., Williams, G., Tam, P., & Tyler, L. K. (2011). White matter changes and word finding failures with increasing age. *PLoS One*, 6(1), e14496, <http://dx.doi.org/10.1371/journal.pone.0014496>.
- Suzuki, W. A. (1996). Neuroanatomy of the monkey entorhinal, perirhinal and parahippocampal cortices: organization of cortical inputs and interconnections with amygdala and striatum. *Seminars in Neuroscience*, 8(1), 3–12, <http://dx.doi.org/10.1006/smns.1996.0002>.
- Suzuki, W. A., & Amaral, D. G. (1994). Perirhinal and parahippocampal cortices of the macaque monkey: cortical afferents. *Journal of Comparative Neurology*, 350(4), 497–533.
- Taylor, K. I., Devereux, B. J., & Tyler, L. K. (2011). Conceptual structure: towards an integrated neurocognitive account. *Language and Cognitive Processes*, 26(9), 1368–1401, <http://dx.doi.org/10.1080/01690965.2011.568227>.
- Taylor, K. I., Moss, H. E., Stamatakis, E. A., & Tyler, L. K. (2006). Binding crossmodal object features in perirhinal cortex. *Proceedings of the National Academy of Sciences of the United States of America*, 103(21), 8239–8244, <http://dx.doi.org/10.1073/pnas.0509704103>.
- Taylor, K. I., & Probst, A. (2008). Anatomic localization of the transentorhinal region of the perirhinal cortex. *Neurobiology of Aging*, 29(10), 1591–1596, <http://dx.doi.org/10.1016/j.neurobiolaging.2007.03.024>.
- Taylor, K. I., Stamatakis, E. A., & Tyler, L. K. (2009). Crossmodal integration of object features: voxel-based correlations in brain-damaged patients. *Brain*, 132(3), 671–683, <http://dx.doi.org/10.1093/brain/awn361>.
- Tyler, L. K., Stamatakis, E. A., Bright, P., Acres, K., Abdallah, S., Rodd, J. M., et al. (2004). Processing objects at different levels of specificity. *Journal of Cognitive Neuroscience*, 16(3), 351–362, <http://dx.doi.org/10.1162/089892904322926692>.
- Vargha-Khadem, F., Gadian, D. G., Watkins, K. E., Connelly, A., Van Paesschen, W., & Mishkin, M. (1997). Differential effects of early hippocampal pathology on episodic and semantic memory. *Science*, 277(5324), 376–380, <http://dx.doi.org/10.1126/science.277.5324.376>.
- Wang, W.-C., Lazzara, M. M., Ranganath, C., Knight, R. T., & Yonelinas, A. P. (2010). The medial temporal lobe supports conceptual implicit memory. *Neuron*, 68(5), 835–842, <http://dx.doi.org/10.1016/j.neuron.2010.11.009>.
- Winblad, B., Palmer, K., Kivipelto, M., Jelic, V., Fratiglioni, L., Wahlund, L.-O., et al. (2004). Mild cognitive impairment—beyond controversies, towards a consensus: report of the international working group on mild cognitive impairment. *Journal of Internal Medicine*, 256(3), 240–246, <http://dx.doi.org/10.1111/j.1365-2796.2004.01380.x>.