



Contents lists available at ScienceDirect

Neurobiology of Learning and Memory

journal homepage: www.elsevier.com/locate/ynlme

Short communication

Parietal lobe critically supports successful paired immediate and single-item delayed memory for targets



Sabine Krumm^{a,*}, Sasa L. Kivisaari^b, Andreas U. Monsch^{a,c}, Julia Reinhardt^d, Stephan Ulmer^{e,f}, Christoph Stippich^{c,d}, Reto W. Kressig^{a,g}, Kirsten I. Taylor^{a,c,h,1}

^a Memory Clinic, University Center for Medicine of Aging Basel, Felix Platter Hospital, Burgfelderstrasse 101, Postfach, CH-4002 Basel, Switzerland

^b Department of Neuroscience and Biomedical Engineering, Aalto University School of Science, PO Box 1510, FI-00076 Aalto, Finland

^c Faculty of Psychology, University of Basel, Missionsstrasse 60/62, CH-4055 Basel, Switzerland

^d Department of Radiology, Division of Diagnostic and Interventional Neuroradiology University Hospital Basel, Petersgraben 4, CH-4031 Basel, Switzerland

^e Department of Radiology and of Neuroradiology, University Hospital Schleswig-Holstein, Arnold-Heller-Strasse 3, Haus 41, D-24105 Kiel, Germany

^f Medical Radiological Institute (MRI), Bahnhofplatz 3, CH-8001 Zurich, Switzerland

^g Faculty of Medicine, University of Basel, Klingelbergstr. 61, CH-4056 Basel, Switzerland

^h Centre for Speech, Language and the Brain, Department of Experimental Psychology, University of Cambridge, Downing Street, Cambridge CB2 3EB, United Kingdom

ARTICLE INFO

Article history:

Received 14 June 2016

Revised 15 March 2017

Accepted 23 March 2017

Available online 24 March 2017

Keywords:

Recognition memory

Parietal lobe

Alzheimer's dementia

Atrophy

Voxel-based morphometry

ABSTRACT

The parietal lobe is important for successful recognition memory, but its role is not yet fully understood. We investigated the parietal lobes' contribution to immediate paired-associate memory and delayed item-recognition memory separately for hits (targets) and correct rejections (distractors). We compared the behavioral performance of 56 patients with known parietal and medial temporal lobe dysfunction (i.e. early Alzheimer's Disease) to 56 healthy control participants in an immediate paired and delayed single item object memory task. Additionally, we performed voxel-based morphometry analyses to investigate the functional-neuroanatomic relationships between performance and voxel-based estimates of atrophy in whole-brain analyses. Behaviorally, all participants performed better identifying targets than rejecting distractors. The voxel-based morphometry analyses associated atrophy in the right ventral parietal cortex with fewer correct responses to familiar items (i.e. hits) in the immediate and delayed conditions. Additionally, medial temporal lobe integrity correlated with better performance in rejecting distractors, but not in identifying targets, in the immediate paired-associate task. Our findings suggest that the parietal lobe critically supports successful immediate and delayed target recognition memory, and that the ventral aspect of the parietal cortex and the medial temporal lobe may have complementary preferences for identifying targets and rejecting distractors, respectively, during recognition memory.

© 2017 The Authors. Published by Elsevier Inc. This is an open access article under the CC BY-NC-ND license (<http://creativecommons.org/licenses/by-nc-nd/4.0/>).

1. Introduction

Studies of recognition memory recently revealed that the parietal lobe (PL) plays a key function in memory processes (Gonzalez et al., 2015; Hutchinson et al., 2014; Olson & Berryhill, 2009), but its precise role is not yet fully understood. One

unresolved question is whether parietal involvement is necessary for or simply supports object memory, and what its role in this process may be with respect to the recognition of familiar items (hits) and the rejection of distractor items (correct rejections). Other open questions include a potential differential involvement of the PL for immediate vs. delayed recognition, and what the relative contributions of PL and medial temporal lobe (MTL) to recognition memory are. The present study addresses some of these issues in healthy controls and patients with known PL and MTL dysfunction, i.e. those with early Alzheimer's Disease (AD).

Functional magnetic resonance imaging (fMRI) studies with healthy individuals have been instrumental in describing the role of the PL in memory processes. The most consistent finding has been that the PL, particularly the ventral parietal cortex (VPC; supramarginal gyrus, angular gyrus, and temporal-parietal

* Corresponding author at: Felix Platter Hospital, University Center for Medicine of Aging Basel, Memory Clinic, Burgfelderstrasse 101, CH-4002 Basel, Switzerland.

E-mail addresses: sabine.krumm@fps-basel.ch (S. Krumm), sasa.kivisaari@aalto.fi (S.L. Kivisaari), andreas.monsch@unibas.ch (A.U. Monsch), julia.reinhardt@usb.ch (J. Reinhardt), sulmer@mri-roentgen.ch (S. Ulmer), christoph.stippich@usb.ch (C. Stippich), reto.kressig@fps-basel.ch (R.W. Kressig), kirsten.taylor@roche.com (K.I. Taylor).

¹ Current address: Neuroscience, Ophthalmology, and Rare Diseases (NORD), Roche Pharma Research and Early Development, Roche Innovation Center Basel, F. Hoffmann-La Roche Ltd, Grenzacherstrasse 124, CH-4070 Basel, Switzerland.

junction), shows significantly greater BOLD activity for hits (targets) than correct rejections (distractors) (Hutchinson et al., 2014; Kahn, Davachi, & Wagner, 2004; Wheeler & Buckner, 2003). Likewise, the VPC is strongly activated for vivid recollections and confident judgments (for review see e.g. Cabeza, Ciaramelli, Olson, & Moscovitch, 2008; Ciaramelli, Grady, & Moscovitch, 2008; Rugg & Curran, 2007; Vilberg & Rugg, 2008; Wagner, Shannon, Kahn, & Buckner, 2005), which are evoked, for example, by qualitative information about the context in which the stimulus was encountered (Tulving, 1985; Wheeler, Stuss, & Tulving, 1997). These findings suggest that the VPC plays a more important role for the recognition of previously acquired target stimuli than for the correct rejection of new distractor stimuli.

To date, studies of patients with PL brain damage have only partially supported the fMRI findings: Ben-Zvi, Soroker, and Levy (2015) found that PL-lesioned patients were impaired on challenging paired associate recognition tasks, while only subtle impairments in recognition decisions were found in other patients with medial and/or lateral PL damage (Berryhill, 2012; Davidson et al., 2008; Schoo et al., 2011), although impaired retrieval of autobiographical memories (Berryhill, Phuong, Picasso, Cabeza, & Olson, 2007) and source memory (Simons, Peers, Mazuz, Berryhill, & Olson, 2010; Simons et al., 2008) have been demonstrated. Additionally, Davidson et al. (2008) found that patients with parietal damage elicited fewer hits (targets) and fewer false recognition decisions than control subjects. These patient studies show that PL damage is associated with subtle memory impairments, but do not unequivocally support the hypothesis that PL is disproportionately more involved in targets relative to distractor decisions.

Non-human primate research demonstrated a densely interconnected network between the posterior parietal cortex and other cortical areas, most notably the MTL. Corticocortical inputs from the inferior parietal lobule are sent to the parahippocampal cortex (Suzuki & Amaral, 1994) and via the entorhinal cortex to the hippocampal formation (Insausti & Amaral, 2008; Kobayashi & Amaral, 2003; Rockland & Hoesen, 1999). This interconnectivity between the inferior parietal lobule and the MTL suggests a functional cooperation between the PL and MTL during cognitive functioning such as memory processes. Indeed, retrieval-related activity, for example, during recollection of contextual details or old/new judgments have been found in MTL as well as PL, suggesting an integrated PL-MTL memory circuit in humans (Daselaar, 2006).

We aimed to determine the extent to which VPC PL integrity is critical for object memory, separately for hits/targets and correct rejection of distractors, and to clarify the relative contributions of the MTL and VPC in these memory processes. We used a memory task in which previously seen pictures (hits/targets) and novel pictures (correct rejections/distractors) were presented and participants had to decide whether the stimuli were old or new. Immediate forced choice recognition of picture pairs after learning trials and delayed recognition of single-items were assessed. We also conducted voxel-based morphometry analyses (DARTEL approach; Ashburner & Friston, 2007) across whole brain grey matter volumes to investigate the functional-neuroanatomic relationships between behavior and voxel-based estimates of atrophy. We addressed these questions in 56 very early AD patients with known PL and MTL dysfunction and 56 demographically matched normal control (NC) individuals. As demonstrated by Budson, Sitarski, Daffner, and Schacter (2002), AD patients tend to commit false positive errors during recognition tasks, which have been linked to perirhinal and hippocampal integrity, especially when stimuli are semantically confusable (Kivisaari, Monsch, & Taylor, 2013). To study the potential contribution of PL to distractor performance independent of a potential contribution of the medial temporal lobe system, we additionally performed analyses using

the memory sensitivity index (d') which controls for general biases in response behavior.

2. Methods

2.1. Participants

56 NCs and 56 patients (PATs) participated under local ethical approval and informed consent was obtained from all participants. The patient group consisted of twenty-six mild AD patients, who were diagnosed according to DSM-IV criteria (American Psychiatric Association, 1994; Mini Mental State Examination (MMSE) ≥ 24 ; Folstein, Folstein, & McHugh, 1975), and 30 amnesic mild cognitive impairment (aMCI) patients, diagnosed according to DSM-IV and Winblad et al. (2004) criteria. Groups were pairwise matched according to sex, age, education, and task order (see section stimuli and task). All healthy control participants had undergone a thorough medical screening to ensure they were neurologically and psychiatrically healthy. In addition, they were administered and received normal scores on the Mini-Mental-State Examination (MMSE; Folstein, Folstein, & McHugh, 1975), California Verbal Learning Task (Delis, Kramer, Kaplan, & Ober, 1987), Clock Drawing Test (Freedman, Leach, Kaplan, Winocur, Schulman, & Delis, 1994), and short version of the Boston Naming Test (Kaplan, Goodglass, & Weintraub, 1978). Nine NCs did not give consent to undergo magnetic resonance imaging (MRI). Therefore, a subsample of 47 NCs (21 male) and 47 demographically matched PATs (24 male; 21 AD, 26 aMCI) underwent anatomic MRI and were included in the voxel-based morphometry (VBM) analyses. Two PATs did not perform the delayed recognition task. Their sex-, age- and education-matched NCs were excluded from behavioral and VBM delayed recognition analyses. Demographic characteristics and MMSE scores are displayed in Table 1.

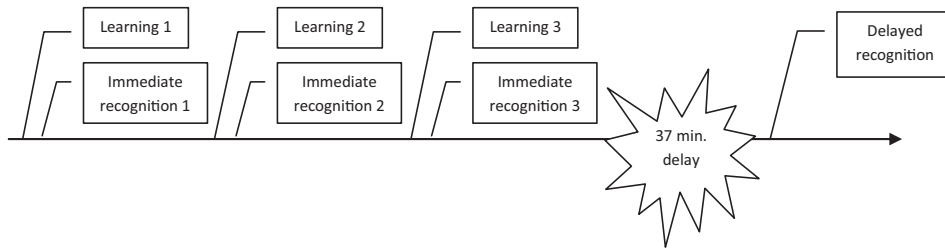
2.2. Stimuli and task

Two sets of 60 realistic, black and white photographs of fruits ($n = 60$) and tools ($n = 60$) were used. Random assignment distributed participants to perform either the tool task before the fruit task, or vice versa, on a computer screen (15 in.) using E-Prime 2.0 (Schneider, Eschman, & Zuccolotto, 2002). Within each semantic category, participants first completed a practice phase on a set of stimuli pairings that did not re-appear in the actual task. After the practice phase the participants performed a learning task where nine pairs of stimuli were presented. This was followed by an immediate forced choice recognition task in which the familiar target pairs were intermixed with 18 novel stimulus pairings (i.e. distractor pairings). Each distractor pair consisted of a photograph that was used in a target pair and a novel photograph. Participants were asked to decide for each stimulus pair whether they had seen it during the learning task or not. Following the standard clinical neuropsychological testing format for episodic learning and memory tests, learning and immediate recognition trials were repeated three times in total using the same stimuli. The procedure is illustrated in Fig. 1. The percentage of correct answers summed from all three immediate recognition trials was analyzed separately for targets and distractor pairings. During the learning trials, pictures were presented for 3 s with an inter-trial interval of 2 s and left-right screen placement within the pairs was counterbalanced over the trials.

After a delay of on average 37 min. ($SD = 13.75$ min.), each picture from the learning task ($n = 36$) was shown individually in the delayed recognition task, in addition to 24 novel pictures. All pictures from the learning task were categorized as target items in delayed recognition and pictures that were shown for the first time

Table 1
Demographic characteristics and MMSE scores.

Variable	Behavioral sample						VBM subsample						Behavioral vs. VBM sample	
	NC		Early AD		NC vs. Early AD		NC		Early AD		NC vs. Early AD		T	p (2-sided)
	N	Mean ± SD	N	Mean ± SD	T	p (2-sided)	N	Mean ± SD	N	Mean ± SD	T	p (2-sided)		
Sex ^a	56	1.46 ± 0.50	56	1.54 ± 0.50	0.751	.454	47	1.49 ± 0.51	47	1.55 ± 0.50	0.614	.541	2.118	.036
Education	56	12.86 ± 2.98	56	12.64 ± 2.97	−0.382	.704	47	12.79 ± 3.09	47	12.64 ± 3.06	−0.234	.815	−1.866	.064
Age	56	75.07 ± 7.01	56	75.16 ± 6.86	0.066	.948	47	74.84 ± 7.27	47	75.07 ± 7.13	0.156	.876	−0.135	.893
MMSE	56	29.25 ± 0.96	56	27.38 ± 2.20	−5.857	.000	47	29.32 ± 0.98	47	27.49 ± 2.04	−5.539	.000	−0.135	.893
Counterbalancing ^b	56	1.46 ± 0.50	56	1.41 ± 0.50	−0.567	.572	47	1.51 ± 0.51	47	1.44 ± 0.50	−0.614	.541	−0.055	.956

^a ♂ = 1; ♀ = 2.^b First performing fruit task, then tool task = 1; first performing tool task, then fruit task = 2.**Fig. 1.** Experiment procedure.

in the delayed recognition task were treated as distractors. Participants were asked if the presented picture was one they had learned in the learning trial or not. In the fruit task, two target items had to be removed from delayed recognition analyses because of an experimenter error (the same picture was presented twice). In the recognition task, stimuli were shown for 5 s or until the participant responded, followed by an inter-trial interval of 1.5 s. During all tasks, pictures were presented in a pseudorandomized order. The experiment procedure is illustrated in Fig. 1.

2.3. MRI acquisition

T1-weighted 3D magnetization-prepared rapid acquisition gradient echo images were collected on a 3T MRI scanner (MAGNETOM Verio, Siemens; inversion time = 1000 ms; repetition time = 2150 ms; echo time = 3.37 ms; flip angle = 7°; rectangular field of view = 87.5%; acquisition matrix = 256 × 224 mm; voxel size = 1.1 mm isotropic) using a 12-channel head coil.

2.4. Whole-brain voxel-based morphometry (VBM)

MRI scans were preprocessed using the DARTEL method (Ashburner & Friston, 2007) in Statistical Parametric Mapping Software (SPM8, Wellcome Institute of Cognitive Neurology, www.fil.ion.ucl.ac.uk) implemented in Matlab 2010 (Mathworks Inc., Sherborn, MA; USA). First, MRI images were segmented into grey matter, white matter and cerebrospinal fluid volumes. Misclassifications of grey matter volume were manually identified by one of the authors (SLK) and the MPRAGE images were segmented again while masking the misclassifications (for more details see Kivisaari, Tyler, Monsch, & Taylor, 2012). The re-segmented grey matter images were coregistered to DARTEL template and normalized to MNI space, modulated and smoothed with 8 mm FWHM Gaussian kernel.

2.5. Analyses

Item analyses were conducted to ensure that only item data were analyzed for which 55% of healthy control participants responded correctly, i.e. greater than chance. In a next step, we

confirmed that the patient group performed significantly better than chance in both the immediate paired-associate and delayed recognition task. Then, remaining items from the tool task and fruit task were pooled (immediate associate task: 36 target pairs and 72 distractor pairs; delayed single-item recognition: 35 target items and 48 distractor items) and an overall percentage correct score was used as a measure of behavioral performance. For all further analyses including VBM, separate percentage correct scores for targets (hits) and distractors (correct rejections) were used, whereby performance in the immediate paired-associate task and delayed single-item recognition was evaluated separately. Behavioral data were analyzed with analyses of covariance (factors: group, target/distractor; covariate: age; IBM SPSS Statistics 21.0). Voxel-based regression analyses related behavioral measures (i.e. % correct hits, % correct rejections) to whole grey matter integrity (covariates: age, total intracranial volume) using a General Linear Model approach in SPM8 (Wellcome Institute of Cognitive Neurology, www.fil.ion.ucl.ac.uk). All mappings were thresholded at $p < 0.001$ or $p < 0.01$ uncorrected at the voxel-level and clusters surviving a random-field corrected $p < 0.05$ are reported in MNI space. Additionally, we conducted separate voxel-based regression analyses with the memory sensitivity index d' (d prime) for the immediate and delayed recognition tasks. This measure reflects the probability of correct hits relative to the overall tendency to give positive recognition responses (hits + positive response bias).

3. Results

3.1. Results of behavioral analyses

Percentage correct was significantly better than chance in both the immediate paired-associate task and delayed single-item recognition and in NCs and PATs (>50%; immediate recognition: PATs, $t(55) = 28.78$, $p = 7.725E^{-35}$; NCs, $t(55) = 56.99$, $p = 1.318E^{-50}$; delayed recognition: PATs, $t(53) = 21.99$, $p = 2.581E^{-21}$; NCs, $t(53) = 90.24$, $p = 1.048E^{-59}$). For both immediate paired-associate task and delayed recognition, NCs performed better than PATs and all participants performed better with targets than distractors, i.e. all participants had greater percentages correct for hits than correct

rejections (immediate recognition: NCs > Pats, $F(1,109) = 53.00$, $p = 5.471E^{-11}$; targets > distractors, PATs $F(1,1005) = 167.74$, $p = 1.365E^{-35}$; NCs, $F(1,1005) = 412.32$, $p = 4.402E^{-77}$; delayed recognition: NCs > Pats, $F(1,105) = 36.15$, $p = 2.691E^{-8}$; targets > distractors, PATs $F(1,987) = 15.35$, $p = 9.600E^{-5}$; NCs, $F(1,987) = 147.50$, $p = 9.883E^{-32}$). Participant group did not interact with target/distractor status in either the immediate paired-associate task ($F(1,2011) = 0.20$, $p = 0.657$) or delayed recognition ($F(1,1957) = 2.74$, $p = 0.098$).

3.2. DARTEL-results

Voxel-based correlation analyses in PATs and NCs were conducted to evaluate the neuroanatomical bases of poorer performance on distractors vs. targets and immediate paired-associate vs. delayed single-item recognition. Poor immediate paired-associate performance for targets was related to reduced volume in right VPC (peak voxel: 31, -49, 45, $t = 5.03$, $p = 3.01E^{-4}$) but not MTL. Poor immediate paired-associate performance for distractors correlated with reduced volume in the right-lateralized MTL including the hippocampus (peak voxel: 29, 3, -18, $t = 4.73$, $p = 2.95E^{-8}$) but not VPC (see Fig. 4). Poor delayed item-recognition performance for targets correlated with reduced volume in right VPC (peak voxel: 30, -48, 46, $t = 4.53$, $p = 0.004$) but not MTL. There were no significant clusters for distractors. Regression plots are provided in Figs. 2 and 3. DARTEL results for key factors are displayed in Fig. 4.

The memory sensitivity measure d' was not associated with grey matter integrity at $p < 0.001$. However, lower memory sensitivity was associated with reduced volume in the parietal cortex, including the precuneus (peak voxel: -24, -46, 62; $t = 3.89$, $p = 0.002$), for delayed single-item recognition (see Fig. 5) at a height threshold of $p < 0.01$. There was no significant association between d' and grey matter integrity in the immediate paired recognition at $p < 0.01$.

4. Discussion

We investigated the PL and MTL contribution to hits and correct rejections in immediate paired-associate and delayed item-

recognition memory. Voxel-based morphometry results demonstrated that right VPC atrophy was associated with fewer hits in both immediate paired-associate and delayed item-recognition memory, but not with performance for distractor items. In contrast, MTL atrophy correlated with increased number of false positives for distractor stimuli in the paired-associate task but not with performance for targets. These results suggest that the VPC and MTL have different but complementary roles in paired- and single-object memory. Additionally, grey matter integrity of the posterior PL, including the precuneus, significantly correlated with delayed recognition performance as measured by d' . These findings support the concept of a parietal memory network (see for example Brodt et al., 2016 or Gilmore, Nelson, & McDermott, 2015), and suggest a discriminative contribution of specific brain areas (e.g. MTL vs. PL) to diverse aspects of item recognition (e.g. targets vs. distractors or paired immediate vs. single-item delayed recognition).

Our findings suggest different neurocognitive processes for the retrieval of target and distractor items. The observed relationship between right VPC and performance with target stimuli corroborates functional imaging studies which link increased activity in this region with previously encountered stimuli (for review see Cabeza et al., 2008 and Wagner et al., 2005). Our findings extend the existing data by suggesting that this region is critical for target memory, and does not merely play a supportive role, possibly due to the importance of this area in vivid recollection (Skinner & Fernandes, 2007). Vivid recollection is based on objective information about the context in which a stimulus was acquired (Tulving, 1985; Wheeler et al., 1997). More remembered details increase the vividness of a recollection and the recognition judgement is made with more confidence. Therefore, target decisions are made more confidently than distractor decisions in healthy participants. As demonstrated by Budson et al. (2002), AD patients are often not able to distinguish between different levels of vividness when trying to recognize a stimulus and are at risk to generate more false positives than cognitively healthy participants (i.e. errors with distractors). Additionally, it is hypothesized that patients perform more poorly with targets than healthy participants because the old items do not trigger highly vivid recollections. This is consistent with a loss of vividness of remembering in patients with dam-

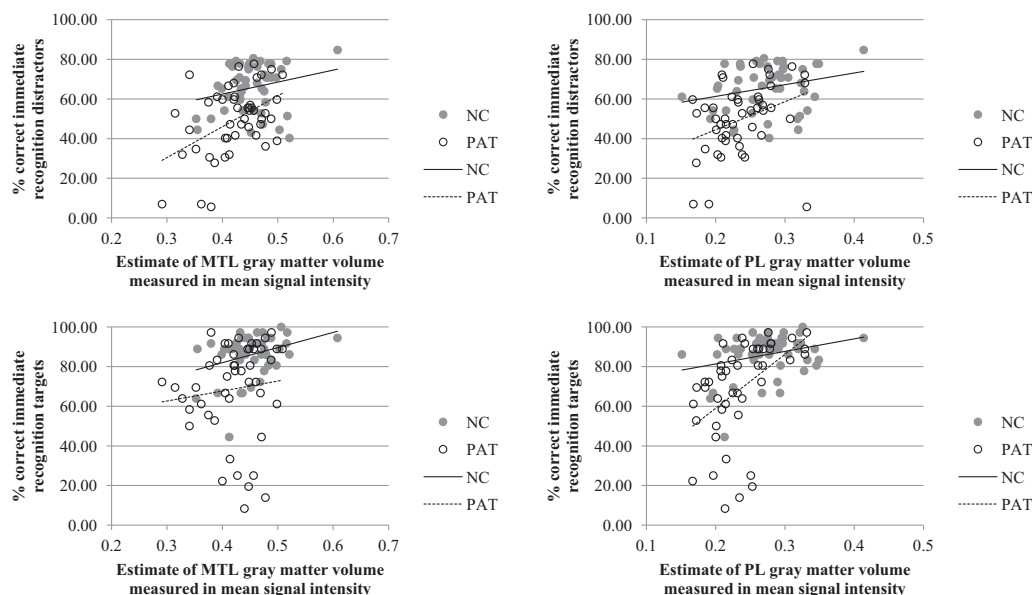


Fig. 2. Scatterplots illustrating the relationship between % correct performance on the immediate paired-associates task and mean signal intensities of PL and MTL regions of interest (spheres of 10 mm diameter centered at MNI coordinates 30, -48, 46 (PL), and 29, 3, -18 (MTL)).

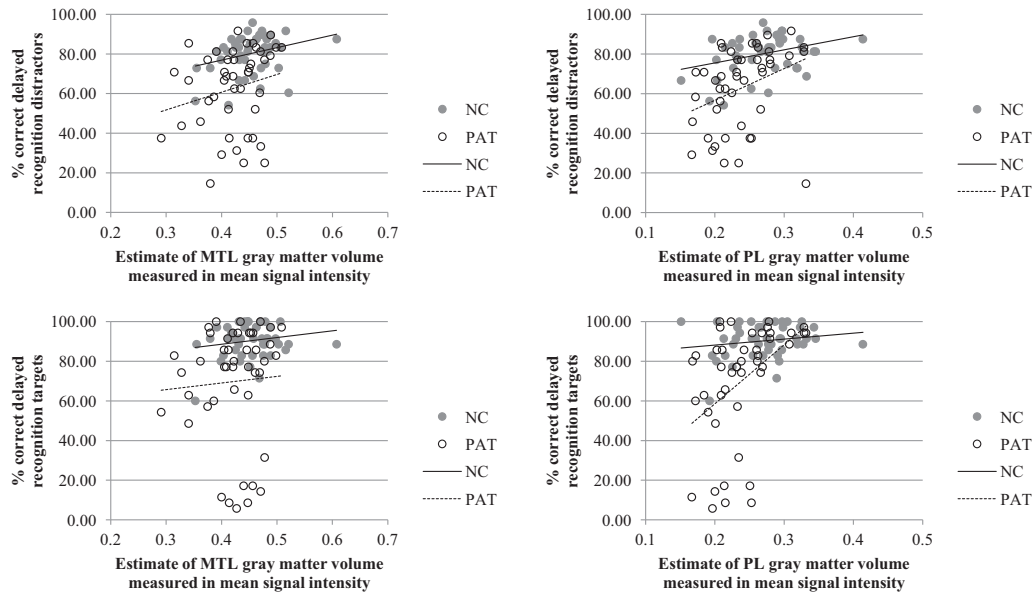


Fig. 3. Scatterplots illustrating the relationship between % correct performance in the delayed item-recognition task and mean signal intensities of PL and MTL regions of interest (spheres of 10 mm diameter centered at MNI coordinates 30, –48, 46 (PL), and 29, 3, –18 (MTL)).

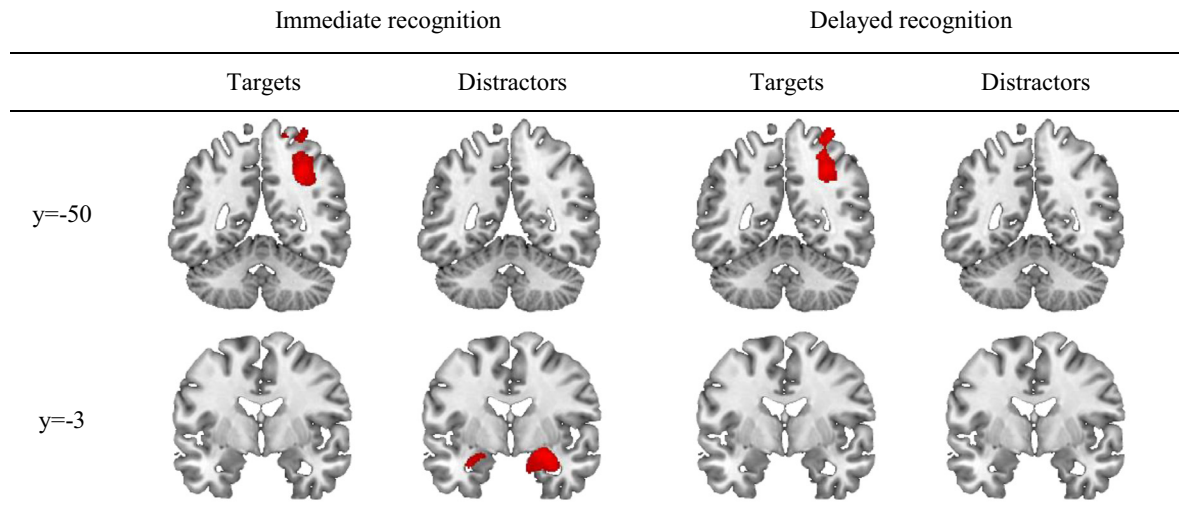


Fig. 4. Significant clusters resulting from the voxel-based regression analyses in PATs and NCs.

age in PL, as reviewed by Skinner and Fernandes (2007). The present finding of a significant relationship between target performance, but not distractor performance, and VPC volume supports this hypothesis. Future studies should include measures of grey matter integrity, picture-based memory tests and rating scales of experienced vividness to further clarify these relationships.

The association between MTL integrity and performance with distractor items is also concordant with recent literature. It has been suggested that the MTL serves a preferential role in rejecting distractor items when these are easily confused with the target objects (see Kivisaari et al., 2013; McTighe, Cowell, Winters, Bussey, & Saksida, 2010). The latter finding may be particularly evident with highly confusable stimuli as in the present task (Kivisaari et al., 2013). In other words, as distractors in our task are very similar to the targets and share many features with them, they are rendered falsely familiar. A strong feeling of familiarity suffices to

incorrectly recognize a distractor item, even though no contextual details about the item are retrieved (Yonelinas, 2002). Therefore, correct rejections of confusable distractors need unique object identification which is putatively supported by the MTL (Kivisaari et al., 2013; McTighe et al., 2010).

AD patients are at risk to commit more false positive errors during item recognition, which may be enhanced when only one stimulus at a time is presented (McTighe et al., 2010). Indeed, this was the motivation for the current design of the paradigm. However, the use of different memory paradigms for immediate (picture pairs) vs. delayed (single pictures) recognition limits the interpretation of our results. MTL integrity was not significantly correlated with delayed recognition performance. This negative finding may reflect the decreased MTL contribution to recognition processes with time, or that the entire MTL more strongly supports associative recognition (e.g. picture pairs) than single-item recognition.

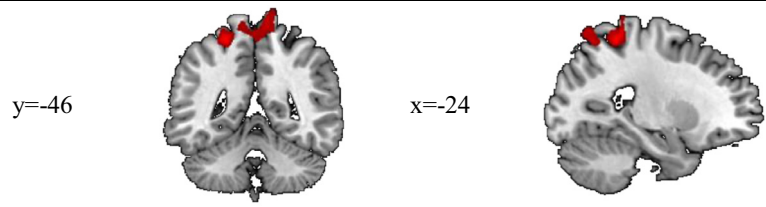


Fig. 5. Clusters in which signal intensity significantly correlated with delayed recognition performance as measured by d' .

The present study design does not enable us to differentiate these two possibilities.

The present results within the PL were restricted to the right hemisphere only. While most studies report an association of the left VPC with target recall (see Levy, 2012 or Wagner et al., 2005 for overviews), more recent patient and imaging studies suggest that the right PL indeed plays a significant role (Bellana, Liu, Anderson, Moscovitch, & Grady, 2016; Ben-Zvi et al., 2015). Moreover, an association of the right PL with target recall is also consistent with the visual rather than verbal nature of our stimuli, and the lack of overt verbal response requirements (Buck, Black, Behrmann, Caldwell, & Bronskill, 1997).

In summary, the present results indicate that the VPC is critically involved in the immediate paired-associate and delayed single-item recognition of previously encountered target stimuli, while MTL integrity was associated with immediate decisions to distractors. Future research will further determine the functional processes driving this VPC involvement in recognition memory.

Acknowledgements

This study was supported by grants from the Swiss National Science Foundation (Ambizione fellowship PZ00P1_126493 [K.I. T.] and grant 3200-049107 [A.U.M.]), the Alfred and Anneliese Sutter-Stöttner Stiftung (A.U.M.), Novartis Foundations, Basel (A. U.M.), Switzerland, and Academy of Finland (286070 [S.L.K.]).

References

- American Psychiatric Association (1994). *DSM-IV: Diagnostic and statistical manual of mental disorders*. Washington, DC: American Psychiatric Press.
- Ashburner, J., & Friston, K. (2007). Voxel-based morphometry. In K. Friston, J. Ashburner, S. Kiebel, T. Nichols, & W. Penny (Eds.), *Statistical parametric mapping: The analysis of functional brain images* (pp. 92–98). Amsterdam: Elsevier.
- Bellana, B., Liu, Z., Anderson, J. A. E., Moscovitch, M., & Grady, C. L. (2016). Laterality effects in functional connectivity of the angular gyrus during rest and episodic retrieval. *Neuropsychologia*, 80, 24–34. <http://dx.doi.org/10.1016/j.neuropsychologia.2015.11.004>.
- Ben-Zvi, S., Soroker, N., & Levy, D. A. (2015). Parietal lesion effects on cued recall following pair associate learning. *Neuropsychologia*, 73, 176–194. <http://dx.doi.org/10.1016/j.neuropsychologia.2015.05.009>.
- Berryhill, M. E. (2012). Insights from neuropsychology: Pinpointing the role of the posterior parietal cortex in episodic and working memory. *Frontiers in Integrative Neuroscience*, 6. <http://dx.doi.org/10.3389/fnint.2012.00031>.
- Berryhill, M. E., Phuong, L., Picasso, L., Cabeza, R., & Olson, I. R. (2007). Parietal lobe and episodic memory: Bilateral damage causes impaired free recall of autobiographical memory. *The Journal of Neuroscience: The Official Journal of the Society for Neuroscience*, 27(52), 14415–14423. <http://dx.doi.org/10.1523/JNEUROSCI.4163-07.2007>.
- Brodth, S., Pöhlchen, D., Flanagin, V. L., Glasauer, S., Gais, S., & Schönauer, M. (2016). Rapid and independent memory formation in the parietal cortex. *Proceedings of the National Academy of Sciences*, 113(46), 13251–13256. <http://dx.doi.org/10.1073/pnas.1605719113>.
- Buck, B. H., Black, S. E., Behrmann, M., Caldwell, C., & Bronskill, M. J. (1997). Spatial- and object-based attentional deficits in Alzheimer's disease. Relationship to HMPAO-SPECT measures of parietal perfusion. *Brain*, 120(7), 1229–1244. <http://dx.doi.org/10.1093/brain/120.7.1229>.
- Budson, A. E., Sitranski, J., Daffner, K. R., & Schacter, D. L. (2002). False recognition of pictures versus words in Alzheimer's disease: The distinctiveness heuristic. *Neuropsychology*, 16(2), 163–173. <http://dx.doi.org/10.1037/0894-4105.16.2.163>.
- Cabeza, R., Ciaramelli, E., Olson, I. R., & Moscovitch, M. (2008). Parietal cortex and episodic memory: An attentional account. *Nature Reviews. Neuroscience*, 9(8), 613–625. <http://dx.doi.org/10.1038/nrn2459>.
- Ciaramelli, E., Grady, C. L., & Moscovitch, M. (2008). Top-down and bottom-up attention to memory: A hypothesis (AtoM) on the role of the posterior parietal cortex in memory retrieval. *Neuropsychologia*, 46(7), 1828–1851. <http://dx.doi.org/10.1016/j.neuropsychologia.2008.03.022>.
- Daselaar, S. M. (2006). Triple dissociation in the medial temporal lobes: recollection, familiarity, and novelty. *Journal of Neurophysiology*, 96(4), 1902–1911. <http://dx.doi.org/10.1152/jn.01029.2005>.
- Davidson, P. S. R., Anaki, D., Ciaramelli, E., Cohn, M., Kim, A. S. N., Murphy, K. J., ... Levine, B. (2008). Does lateral parietal cortex support episodic memory? *Neuropsychologia*, 46(7), 1743–1755. <http://dx.doi.org/10.1016/j.neuropsychologia.2008.01.011>.
- Delis, D. C., Kramer, J. H., Kaplan, E., & Ober, B. A. (1987). *California Verbal Learning Test*. San Antonio, TX: Psychological Corporation.
- Folstein, M. F., Folstein, S. E., & McHugh, P. R. (1975). "Mini Mental State" – A practical method for grading the cognitive state of patients for the clinician. *Journal of Psychiatry Research*, 12, 189–198.
- Freedman, M., Leach, L., Kaplan, E., Winocour, G., Schulman, K. I., & Delis, D. C. (1994). *Clock Drawing. A Neuropsychological Analysis*. New York: Oxford University Press.
- Gilmore, A. W., Nelson, S. M., & McDermott, K. B. (2015). A parietal memory network revealed by multiple MRI methods. *Trends in Cognitive Sciences*, 19(9), 534–543. <http://dx.doi.org/10.1016/j.tics.2015.07.004>.
- Gonzalez, A., Hutchinson, J. B., Uncapher, M. R., Chen, J., LaRocque, K. F., Foster, B. L., ... Wagner, A. D. (2015). Electrooculography reveals the temporal dynamics of posterior parietal cortical activity during recognition memory decisions. *Proceedings of the National Academy of Sciences*, 112(35), 11066–11071. <http://dx.doi.org/10.1073/pnas.1510749112>.
- Hutchinson, J. B., Uncapher, M. R., Weiner, K. S., Bressler, D. W., Silver, M. A., Preston, A. R., & Wagner, A. D. (2014). Functional heterogeneity in posterior parietal cortex across attention and episodic memory retrieval. *Cerebral Cortex*, 24(1), 49–66. <http://dx.doi.org/10.1093/cercor/bhs278>.
- Insausti, R., & Amaral, D. G. (2008). Entorhinal cortex of the monkey: IV. Topographical and laminar organization of cortical afferents. *The Journal of Comparative Neurology*, 509(6), 608–641. <http://dx.doi.org/10.1002/cne.21753>.
- Kahn, I., Davachi, L., & Wagner, A. D. (2004). Functional-neuroanatomic correlates of recollection: Implications for models of recognition memory. *The Journal of Neuroscience: The Official Journal of the Society for Neuroscience*, 24(17), 4172–4180. <http://dx.doi.org/10.1523/JNEUROSCI.0624-04.2004>.
- Kaplan, E. F., Goodglass, H., & Weintraub, S. (1978). *The Boston Naming Test*. Boston: Veterans Administration Medical Center.
- Kivisaari, S. L., Monsch, A. U., & Taylor, K. I. (2013). False positives to confusable objects predict medial temporal lobe atrophy. *Hippocampus*, 23(9), 832–841. <http://dx.doi.org/10.1002/hipo.22137>.
- Kivisaari, S. L., Tyler, L. K., Monsch, A. U., & Taylor, K. I. (2012). Medial perirhinal cortex disambiguates confusable objects. *Brain*, 135(12), 3757–3769. <http://dx.doi.org/10.1093/brain/aws277>.
- Kobayashi, Y., & Amaral, D. G. (2003). Macaque monkey retrosplenial cortex: II. Cortical afferents. *The Journal of Comparative Neurology*, 466(1), 48–79. <http://dx.doi.org/10.1002/cne.10883>.
- Levy, D. A. (2012). Towards an understanding of parietal mnemonic processes: Some conceptual guideposts. *Frontiers in Integrative Neuroscience*, 41.
- McTigue, S. M., Cowell, R. A., Winters, B. D., Bussey, T. J., & Saksida, L. M. (2010). Paradoxical false memory for objects after brain damage. *Science (New York, N. Y.)*, 330(6009), 1408–1410. <http://dx.doi.org/10.1126/science.1194780>.
- Olson, I. R., & Berryhill, M. (2009). Some surprising findings on the involvement of the parietal lobe in human memory. *Neurobiology of Learning and Memory*, 91(2), 155–165. <http://dx.doi.org/10.1016/j.nlm.2008.09.006>.
- Rockland, K. S., & Hoesen, G. W. V. (1999). Some temporal and parietal cortical connections converge in CA1 of the primate hippocampus. *Cerebral Cortex*, 9(3), 232–237. <http://dx.doi.org/10.1093/cercor/9.3.232>.
- Rugg, M. D., & Curran, T. (2007). Event-related potentials and recognition memory. *Trends in Cognitive Sciences*, 11(6), 251–257. <http://dx.doi.org/10.1016/j.tics.2007.04.004>.
- Schneider, W., Eschman, A., & Zuccolotto, A. (2002). *E-prime (version 2.0). Computer software and manual*. Pittsburgh, PA: Psychology Software Tools Inc..
- Schoo, L. A., van Zandvoort, M. J. E., Biessels, G. J., Kappelle, L. J., Postma, A., & de Haan, E. H. F. (2011). The posterior parietal paradox: Why do functional magnetic resonance imaging and lesion studies on episodic memory produce

- conflicting results? *Journal of Neuropsychology*, 5(Pt 1), 15–38. <http://dx.doi.org/10.1348/174866410X504059>.
- Simons, J. S., Peers, P. V., Hwang, D. Y., Ally, B. A., Fletcher, P. C., & Budson, A. E. (2008). Is the parietal lobe necessary for recollection in humans? *Neuropsychologia*, 46(4), 1185–1191. <http://dx.doi.org/10.1016/j.neuropsychologia.2007.07.024>.
- Simons, J. S., Peers, P. V., Mazuz, Y. S., Berryhill, M. E., & Olson, I. R. (2010). Dissociation between memory accuracy and memory confidence following bilateral parietal lesions. *Cerebral Cortex*, 20(2), 479–485. <http://dx.doi.org/10.1093/cercor/bhp116>.
- Skinner, E. I., & Fernandes, M. A. (2007). Neural correlates of recollection and familiarity: A review of neuroimaging and patient data. *Neuropsychologia*, 45(10), 2163–2179. <http://dx.doi.org/10.1016/j.neuropsychologia.2007.03.007>.
- Suzuki, W. A., & Amaral, D. G. (1994). Perirhinal and parahippocampal cortices of the macaque monkey: Cortical afferents. *The Journal of Comparative Neurology*, 350, 497–533.
- Tulving, E. (1985). Memory and consciousness. *Canadian Psychology*, 26, 1–12.
- Vilberg, K. L., & Rugg, M. D. (2008). Memory retrieval and the parietal cortex: A review of evidence from a dual-process perspective. *Neuropsychologia*, 46(7), 1787–1799. <http://dx.doi.org/10.1016/j.neuropsychologia.2008.01.004>.
- Wagner, A. D., Shannon, B. J., Kahn, I., & Buckner, R. L. (2005). Parietal lobe contributions to episodic memory retrieval. *Trends in Cognitive Sciences*, 9(9), 445–453. <http://dx.doi.org/10.1016/j.tics.2005.07.001>.
- Wheeler, M. E., & Buckner, R. L. (2003). Functional dissociation among components of remembering: control, perceived oldness, and content. *The Journal of Neuroscience*, 23(9), 3869–3880.
- Wheeler, M. A., Stuss, D. T., & Tulving, E. (1997). Toward a theory of episodic memory: The frontal lobes and autonoetic consciousness. *Psychological Bulletin*, 121, 334–354.
- Winblad, B., Palmer, K., Kivipelto, M., Jelic, V., Fratiglioni, L., Wahlund, L.-O., ... Petersen, R. C. (2004). Mild cognitive impairment – Beyond controversies, toward a consensus: Report of the International Working Group on Mild Cognitive Impairment. *Journal of Internal Medicine*, 256, 240–246.
- Yonelinas, A. P. (2002). The nature of recollection and familiarity: A review of 30 years of research. *Journal of Memory and Language*, 46, 441–517.